



A CASE REPORT OF ENDOSCOPIC CERVICAL LAMINECTOMY FOR REDUCTION OF C6-7 BILATERAL FACET DISLOCATION

Lin Zhang, *Zexing Zhu, An Xiao, Bo Zhu, Baowei Liu and Xifeng Zhang

301 Hospital, Military Spine Center of the PLA

ARTICLE INFO

Article History:

Received 14th June, 2017
Received in revised form
18th July, 2017
Accepted 02nd August, 2017
Published online 30th September, 2017

Key words:

Laminectomy,
Transforaminal,
Percutaneous.

*Corresponding author

Copyright ©2017, Lin Zhang et al. This is an open access article distributed under the Creative Commons Attribution License, which permits unrestricted use, distribution, and reproduction in any medium, provided the original work is properly cited.

Citation: Lin Zhang, Zexing Zhu, An Xiao, Bo Zhu, Baowei Liu and Xifeng Zhang. 2017. "A Case Report of Endoscopic Cervical Laminectomy for Reduction of C6-7 Bilateral Facet Dislocation", *International Journal of Development Research*, 7, (09), 15075-15078.

INTRODUCTION

Cervical bilateral facet dislocation can be devastating. The incidence in the literature is 50%-84%, mostly resulting in complete and incomplete spinal cord lesions and quadriplegia. Delays in diagnosis or failure of reset can lead to even worse poor outcomes (Nagata *et al.*, 2017). The most common causes of cervical bilateral facet dislocation include sports injuries; direct head-loading injuries, motor vehicle accidents, and falls. For unilateral cervical dislocation, skull traction is effective and the most widely used method of acute management. It is, however, usually unsuccessful for bilateral facet cervical dislocation because of the more tightly locked articular processes of facet (Vikram Chakravarthy, 2014). In this situation, we have to unlock the vertebra joints by a posterior cervical open operation, then roll the patient over and perform open fusion and fixation by the anterior cervical approach (Lines, 2016; Duan *et al.*, 2016).

As a result, it can lead to further neurologic deterioration due to the trauma of open surgical reduction. We present a case of cervical bilateral facet dislocation, reset by a visualized percutaneous minimally invasive technique with local anesthesia. No study has yet reported this technique for cervical bilateral facet dislocation.

Case Report

On Dec. 28th 2016, a 50-year-old woman was working in the fields, when a betel nut trunk fell and hit her neck. She felt dizzy and nausea immediately and lost her consciousness for ten minutes. She became immobilized when recovered consciousness, complaining of neck pain and exhibits signs of paraplegia. She presented to the emergency department 9 hours later with insensibility and immobility of her abdomen and lower limbs. A computed tomography (CT) scan of her cervical vertebrae showed bilateral C6-C7 facet dislocation with locking of the C7 superior articular process dorsal to the

ABSTRACT

For unilateral cervical dislocation, skull traction is one of the standard first treatment protocol and most effective treatments, but it is usually unsuccessful for the bilateral cervical dislocation because of the more tightly locked articular processes. In this situation, we have to unlock the vertebra joints by a posterior cervical approach operation, then roll the patient over and take another operation of fusion and fixation by the anterior cervical approach.

Anthony Yeung of the United States for the transforaminal visualized YESS endoscopic technique mostly influences the percutaneous minimally invasive techniques adopted in China. It is technically feasible and safe for cervical laminectomy since it emphasizes visualization, but with the aid of an endoscope.

Method: Local anesthesia.

- The assistant holds the skull traction in his hands.
- The superior articular process and lamina of C7 is visualized by the endoscope.
- One cervical facet joint is reduced by partial resection of the dislodged facet, then the contralateral side is also reset with the aid by manual cervical traction

C6 inferior articular process bilaterally as well as laminae fracture. The C6 moved forward relative to C7, which led to spinal cord compression by the facet joints. (Figure 1). Magnetic resonance imaging (MRI) demonstrated spinal cord compression and edema. Physical examination in the emergency department was showed in Table 1 and TLICS scoring was 8 points.

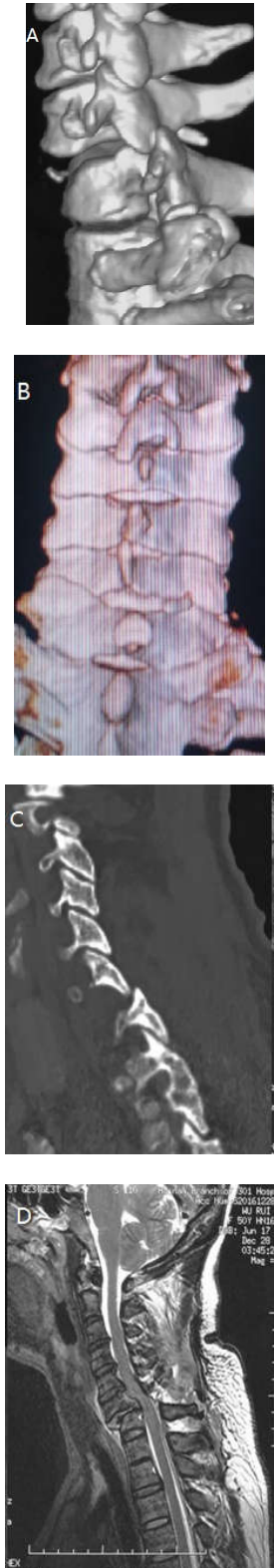
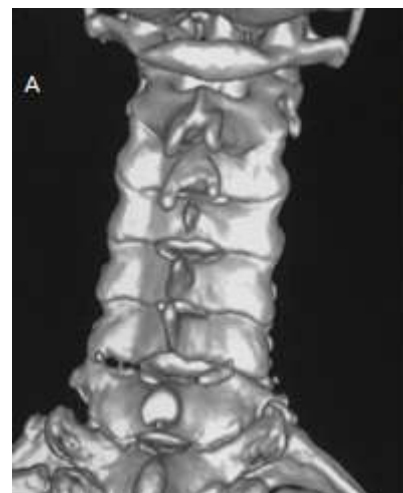

Figure 1: A: The anterior part fracture of superior endplate of C7. B: Bilateral C6-C7 facet locked and the C7 right superior articular process and laminae fracture. C: The locking of the C7 superior articular process dorsal to the C6 inferior articular process. D: Spinal cord compression in MRI.

Table 1. The physical examination in the emergency department

Physical examination :			
	Sense	Strength	Reflex
Upper limb	Normal	Flex elbow IV (bilateral) Extend elbow III (bilateral) Hand gripping III (bilateral)	negative
Lower limb	Insensible except the second toe of left foot	0 level	negative
Trunk	Senseless and moveless from manubrium		perianal reflex normal

After Admission to the EICU, the patient was treated with intravenous fluids and glucocorticoid pulse therapy, as well as the skull traction. At the same time, the patient was instructed to learn abdominal breathing and expectoration in the supine position, because of the weakness of intercostal muscle. Two weeks later, the patient was transferred to the orthopedic department with stable vital signs, but the skull traction for reduction failed, and the TLICS score was still 8 points. So we decided to unlock the vertebra joints with the percutaneous minimally invasive visualized technique by local anesthesia. Preoperative plan deduced the maximum resistance to reset was on the locking of the C7 superior articular process dorsal to the C6 inferior articular process on the left, because there were fractures of the superior articular process and laminae of C7 on the right. We located the locking point of C7 superior articular process on the left by x-ray fluoroscopy and infiltrated from the skin to the facet joint and laminae with local anesthesia of 1% lignocaine. An 18-gauge needle was inserted along the guiding wire to the target. Then a stab incision of about 6 mm was made, and following the stepwise-dilating cannulas, the spine endoscope was pushed on the dorsa of left superior articular process of C7. The assistant held skull traction with his hands, when the Surgeon removed the superior border of left superior articular process and part of lamina of C7 by an electric grinder visualized by the endoscope. The left vertebra joint was reduced with a sudden snapping vibration like clicking hip, and the right side was also reduced secondarily (Figure2). The patient reported that the pain in her neck was relieved immediately and paralysis plane down to the thigh during the operation. The postoperative CT showsEd that bilateral C6-C7 facet dislocation was reduced. The postoperative MRI demonstrated spinal cord compression was relieved completely. The patient had another operation of fusion and fixation by the anterior cervical approach with general analgesia one week later. X-ray fluoroscopy was presented in Figure2 (D, E).



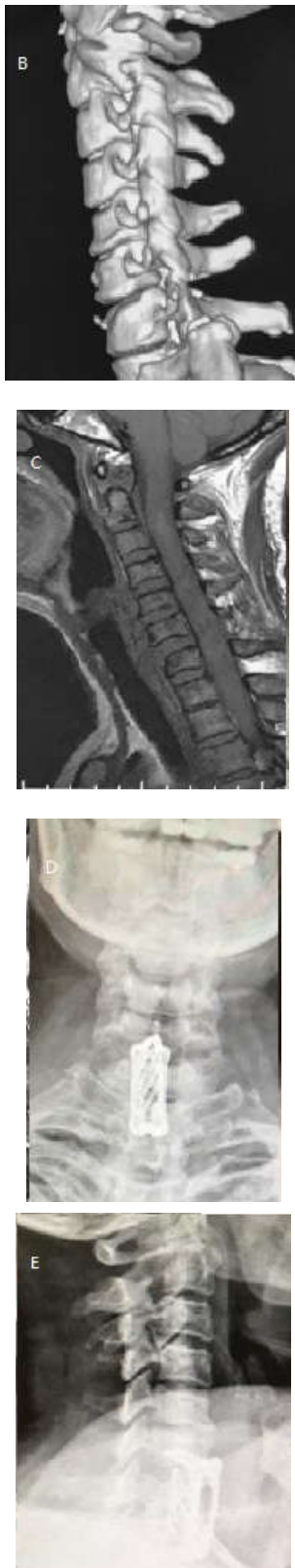

Figure2: A: the electric grinder in the endoscope removed the superior border of left superior articular process and part of lamina of C7. B and C: The cervical dislocation was reduced and the spinal cord compression was relieved completely. D and E: The operation of fusion and fixation by the anterior cervical approach.

DISCUSSION

The most common causes of cervical facet dislocation include sports accidents; direct head-loading injuries, motor vehicle accidents and falls (Nagata *et al.*, 2017).

For the unilateral cervical dislocation, the skull traction is the most effective treatment of acute management (Chen, 2016). Most of unilateral cervical dislocation can be reduced with the skull traction in two weeks. When the superior articular process locked on the dorsa of inferior articular process of upper vertebral is drawn back, the dislocation is reset like pulling the trigger. But the two-week skull traction is usually useless for the bilateral facet cervical dislocation because of the more tightly locked articular process of double-side facets. The 50%-84% patients of cervical bilateral facet dislocation occur complete spinal cord lesions and quadriplegia. Delays in diagnosis or failure of reset can lead to even worse poor outcomes [1]. In this situation, we have to unlock them by a posterior cervical approach open surgical operation first, and then roll the patient over and take another operation of fusion and fixation by the anterior cervical approach (Zhang *et al.*, 2016). It is traumatic and can lead to further neurologic deterioration.

The percutaneous minimally invasive techniques adopted in China are mostly influenced by Anthony Yeung of the United States for the transforaminal visualized YESS technique (Yeung *et al.*, 2007). With the characteristics of efficiency and minimally invasive, it is becoming more and more popular and widely used from lumbar spine to cervical spine (Yeung, 2017; Yeung, 2014). It is feasible and safe for cervical laminectomy, so the percutaneous minimally invasive visualized technique can pull this trigger much easier in a stab incision of about 6 mm with local anesthesia (Yeung, 2007). It is also safer than traditional open surgical operation, because the patient can tell the surgeon her feeling during the operation. This technique could reduce postoperative recovery times, complications and acute care costs (Yeung, 2003; Yeung, 1999). Despite the application of cervical spine in clinic is increasing, no study has yet reported the percutaneous minimally invasive visualized technique for cervical bilateral facet dislocation.

Conclusion

The percutaneous minimally invasive visualized technique can take the place of traditional open surgical operation to reset the cervical bilateral facet dislocation more safely and effectively.

Acknowledgements

Thanks to Dr Anthony Yeung's introduction of endoscopic technical inventions, his creation and expansion of the technique, his perseverance and promotion in China. 2003 I visited Anthony Yeung and learned the technology and technique. Now Chinese doctors and patients, because of the many advantages of endoscopic techniques, such as fewer traumas, rapid recovery, and a minimal complication rate, are increasingly welcoming the endoscopic MIS surgery. It will reach more people who are currently underserved. Also, I would like to thank Lin Zhang for the patient's doctor in charge, Zexing Zhu for data collection and paper writing. Last but not the least, I would like to thank An Xiao, Bo Zhu and Baowei Liu, who completed this case as assistants.

REFERENCES

- Chen QM, Chen QX. Multivariate analysis for prognostic factors on non-operative treatment of cervical spinal cord injury without fracture or dislocation]. *Zhongguo Gu Shang*. 2016 Mar; 29(3): 242-7. Chinese.

- Duan C, Hu J, Wang X, Wu J. Early and one-stage posterior-anterior surgery for fresh and severe lower cervical spine fracture and dislocation. *Zhong Nan Da Xue Xue Bao Yi Xue Ban*. 2016 Aug; 41(8): 838-45.
- Lines CC, Prado DT, Joaquim AF. Surgical treatment of traumatic cervical facet dislocation: anterior, posterior or combined approaches? *Arq Neuropsiquiatr*. 2016 Sep; 74(9): 745-749.
- Nagata K, Inokuchi K, Chikuda H, Ishii K, Kobayashi A, Kanai H, Nakarai H, Miyoshi K. Early versus delayed reduction of cervical spine dislocation with complete motor paralysis: a multicenter study. *Eur Spine J*. 2017 Apr; 26(4): 1272-1276.
- Vikram Chakravarthy, BS, 1 Jeffrey P. Mullin, MD Neurologically Intact Patient Following Bilateral Facet Dislocation: Case Report and Review of Literature *The Ochsner Journal* 14:108–111, 2014
- Yeung AT 2017. Transforaminal Endoscopic Decompression for Painful Degenerative Conditions of The Lumbar Spine: A review of One Surgeon's Experience with Over 10,000 Cases Since 1991. *J Spine Neurosurg* 6:2.
- Yeung AT, Yeung CA. 2003. Advances in endoscopic disc and spine surgery: foraminal approach. *Surg Technol Int*; 11:255-63.
- Yeung AT, Yeung CA. 2007. Minimally invasive techniques for the management of lumbar disc herniation. *Orthop Clin North Am*. 2007 Jul; 38(3): 363-72;
- Yeung AT. 1999. Minimally Invasive Disc Surgery with the Yeung Endoscopic Spine System (YESS). *Surg Technol Int*. 8:267-77.
- Yeung AT. 2007. The Evolution and Advancement of Endoscopic Foraminal Surgery: One Surgeon's Experience Incorporating Adjunctive Technologies. *SAS J*. Aug 1; 1(3): 108-17.
- Yeung AT. 2014. Foreword, Percutaneous and Endoscopic MIS Special Issue. *Int J Spine Surg*. Dec 1; 8
- Zhang L, Sun Y, Jiang C, Zuo L, Shen H, Hu G, Wang Y, Chen A, Wu F, Yu M, Diao Y, Liu N Dorsal open reduction with pedicle screw rod internal fixation for lower cervical spine dislocation: A retrospective analysis of 12 cases. *Neurochirurgie*. 2016 Oct; 62(5): 245-250.
