



PREVALENCE OF LEIOMYOMA IN PATIENTS WITH ABNORMAL UTERINE BLEEDING

* Jinonath, S.K., Dr. Hephzibah Kirubamani, N. and Dr. Vanusha, A.

¹Final year Medical student

²Obstetrics Gynaecology Saveetha Medical College & hospital, Saveetha University, Thandalam

³Senior resident- Obstetrics Gynaecology Saveetha Medical College & hospital, Saveetha University, Thandalam

ARTICLE INFO

Article History:

Received 04th August 2017

Received in revised form

26th September, 2017

Accepted 11th October, 2017

Published online 29th November, 2017

Key Words:

Abnormal Uterine Bleeding,
Fibroid, Myomectomy,
hysterectomy,
Fibroid Polyp.

*Corresponding author

Copyright ©2017, Jinonath et al. This is an open access article distributed under the Creative Commons Attribution License, which permits unrestricted use, distribution, and reproduction in any medium, provided the original work is properly cited.

Citation: Jinonath, S.K., Dr. Hephzibah Kirubamani, N. and Dr. Vanusha, A., 2017. "Prevalence of leiomyoma in patients with Abnormal Uterine Bleeding", *International Journal of Development Research*, 7, (11), 16668-16670.

ABSTRACT

Women with Abnormal Uterine Bleeding is the most commonest presenting symptom for which they report to gynaecology out-patient department. This is more commonly associated with leiomyoma. Objective of the study was to find out the prevalence of Leiomyoma in patients presenting with Abnormal Uterine Bleeding in reproductive and perimenopause age group. A retrospective study was conducted from June 2016 to June 2017. Records of 128 patients who presented with Abnormal Uterine Bleeding were collected from Medical record room and were analysed. 72% belong to 30-40 years and 86% undergone sterilization. Heavy menstrual bleeding was the dominant clinical presentation in 84%. Correlation of clinical and USG diagnosis was 99% and 68% had intramural fibroid. 3.5% opted for medical treatment and for fibroid with cancer cervix 0.5% had chemo radiation. Those who had surgery 98% fibroid was confirmed Histopathologically. Leading cause of AUB in our study was leiomyoma

INTRODUCTION

Abnormal uterine bleeding in any period of life is considered serious and it accounts to a high percentage of out patient department attendance. Abnormal uterine bleeding occurs in 9 to 14 percent of women between menarche and menopause, significantly impacting quality of life. Abnormal uterine bleeding is of considerable clinical significance because of its numerous structural and non structural causes. Leiomyoma is the most frequent benign lesion that causes abnormal uterine bleeding. The prevalence of this disease ranges from 60% to 80% in women of reproductive age. Although sometimes asymptomatic, uterine leiomyoma may cause menorrhagia, dysmenorrhea, abdominal mass, distention, bloating, increased urinary frequency and constipation, and subfertility, as well as atypical symptoms such as compression symptoms, which are uncommon. Uterine leiomyomas are diverse in size and location and these characteristics affect the types of symptoms seen and can be diagnosed clinically confirmed by USG examination and after surgery by histopathological.

MATERIALS

A retrospective study was conducted from April 2016 to April 2017 at Saveetha Medical College Gynaec Department, Saveetha university. Records of 128 patients who presented with Abnormal Uterine Bleeding were collected from Medical record room and were analysed. Demographic details, symptoms, how long they had the symptoms, clinical findings, USG report, whether blood transfusion was given, and the management offered and underwent were analysed

RESULTS

Table 1 depicts the age group & parity distribution. 6% belong to 25-30 years, 24% belong to 31-35 years 48% of them between 36-40 years and 41-45 years 14%. 72% belong to 30-40 years. Highest number of AUB due to fibroid was seen in Para2 about 54% followed by 28% in para3. Different symptoms for which they were admitted and their duration shown in Table 2.

Table 1. Distribution of Age group & parity distribution

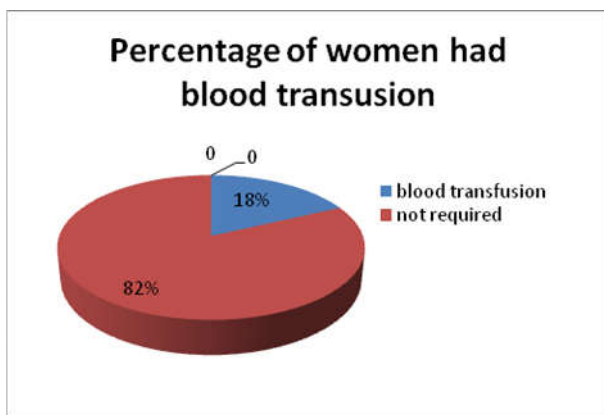
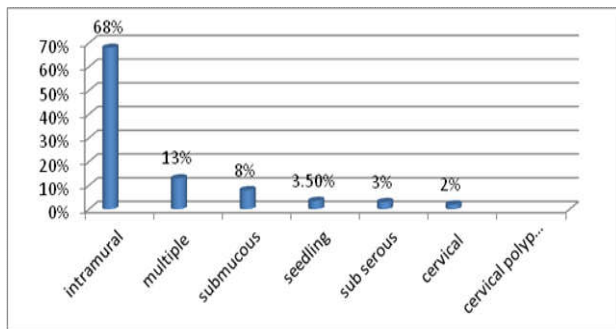
Age group	Percentage	Parity	percentage
25 -30	6%	unmarried /Para1	2% / 4%
31-35	24%	Para 1 /Para2/ Para3	8% / 12% /4%
36-40	48%	Para2/Para3	32% / 16%
41-45	14%	Para2/Para3/Para4	8% / 4% / 2%
46-50	8%	Para2 /Para3 / Para4	2% /4%/2%

72% belong to 30-40years. Highest number of AUB due to fibroid was seen in Para2 about54% followed by 28% in para3.

Table 2. Symptoms & its duration

Symptoms	Percentage	Duration	Percentage
Heavy Menstrual bleeding(HMB)	84%	Less than 6 months	7%
		More than 6months	77%
Mass abdomen with HMB	12%	Less than 6 months	10%
		More than 6months	2%
Intermenstrual bleeding with vaginal discharge	4%	Less than 6 months	1%
		More than 6months	3%

18% reported early because of associated symptoms like fatigue, not able to do routine work due to anaemia.

**Fig. 1. Percentage of women required blood transfusion**

In this study 68 % had intramural fibroid and 99% USG findings correlated with clinical findings

Table 3. Different management selected by patient

Type of management suggested	Percentage of the women accepted
Medical	3.5%
Surgery	96%
Uterine artery embolisation	Nil
Chemo radiation	0.5%

96% opted surgery as they want permanent solution

Table 4. Management undergone

Type of the procedure	Percentage
Hysterectomy	94%
Myomectomy	1%
Polypectomy	1%
Medical	3.5%
Chemoradiation	0.5%

For fibroid polyp with cancer cervix chemo radiation was suggested by oncologist

Table 5. Histopathology Report

Myometrium	Percentage	Endometrium	Percentage
Fibromyoma	98%	Proliferative phase	58.3%
Adenomyosis	2%	Secretary phase	12.6%
		Simple hyperplasia	28.6%
		Fibroid polyp with cancer cervix	0.5%

Myometrium showed 98% fibromyoma and Endometrium showed 58.3% secretary phase

Majority 84% had heavy menstrual bleeding. Fig1 indicates 18% required preoperative blood transfusion and they reported early because of associated symptoms like fatigue not able to do routine work due to anaemia. Fig2 shows USG findings 68% showed Intramural, Sub serous -3% Multiple fibroid 13%. Seedling fibroid -3.5% Sub mucous- 8% Cervical fibroid -2% Expanded cervix suggestive of Cervical polyp-1.5%, Adenomyosis-1% .Trans abdominal USG was done in 92% and TVS done in 8% Table 3 shows different management selected by patient and 96% had given consent for surgery. Table4 indicates management undergone by the patient : In 3.5% women had Medical management namely NSAIDs along with combined oral contraceptives, Myomectomy -1% hysterectomy - 94%, Polypectomy - 1% Fibroid with cancer cervix - Chemo radiation -0.5 % Table5 shows Histopathological examination of myometrium and 98.4% fibromyoma, followed by 2 .6% Adenomyosis. Histopathology of endometrium revealed Proliferative endometrium in 58.3% secretary endometrium 12.6 % simple hyperplasia 28.6, fibroid polyp with cancer cervix 0.5%

DISCUSSION

Most common complaint was heavy menstrual bleeding in our study which is similar to study of Jetley et al. and Shobha. Most common indication for hysterectomy is fibroid as stated in Talener DE et al study .In our study majority of the women opted for hysterectomy of since they wanted permanent solution in this group ,72% of them both ovaries were left behind. In the studies done by Khare ,endometrial hyperplasia in 23%, In Bharat Talukdar study, HPE confirmed endometrial hyperplasia in 56.31% of cases but in our study 28.6 % simple endometrial hyperplasia and 58.3 % had proliferative endometrium. In our study 99% was diagnosed by USG , in Dueholm et al USG diagnosis of leiomyoma was 89.13%

Conclusion

Leading cause of AUB in our study was fibroid and commonest symptom was heavy menstrual bleeding and there was a good correlation between clinical, USG and histopathology.

Acknowledgement

We thank chancellor, Director, Dean of Saveetha Medical college & hospital, Saveetha university for permitting to conduct successfully.

REFERENCES

Bharat Talukdar and Sangita Mahela1 Abnormal uterine bleeding in perimenopausal women: Correlation with sonographic findings and histopathological examination of

- hysterectomy specimens: *Journal of Midlife Health*. 2016 Apr-Jun; 7(2): 73–77.
- Dueholm M, Lundorf E, Hansen ES, Ledertoug S, Olesen F. 2002. Accuracy of magnetic resonance imaging and transvaginal ultrasonography in the diagnosis, mapping, and measurement of uterine myomas. *American Journal of Obstet Gynecol*.186:409–15
- Jetley S, Rana S, Jairajpuri ZS. 2013. Morphological spectrum of endometrial pathology in middle-aged women with atypical uterine bleeding: A study of 219 cases. *Journal of Midlife Health*.4:216–20
- Khare A, Bansal R, Sarma S, Elhence P, Makkar N, Tyagi Y. 2012. Morphological spectrum of endometrium in patients presenting with dysfunctional uterine bleeding. *People journal Science Research*.5:13–6.
- Shobha PS. 2014. Sonographic and histopathological correlation and evaluation of endometrium in perimenopausal women with abnormal uterine bleeding. *International Journal of Reproduction Contraception Obstet Gynaecol*. 3:113–7.
- Telner DE, Jakubovicz D. 2007. Approach to diagnosis and management of abnormal uterine bleeding. *Canadian Family Physician*.53:58–64
