



CASE REPORT

OPEN ACCESS

OSSEOUS AND MYELOID METAPLASIA IN CHRONIC PYELONEPHRITIS

¹Dr. Deepti Gupta, ²Dr. Anjali Tewari, ³Dr. Nupur Trivedi, ⁴Dr. Shefali Agarwal
and ⁵Dr. Asha Agarwal

¹Consultant Pathologist, Regency Hospital, A-2 Sarvodaya Nagar, Kanpur 208005, U. P
²HOD and Consultant Pathologist, Regency Hospital, A-2 Sarvodaya Nagar, Kanpur 208005, U. P
^{3,4,5} Consultant Pathologist, Regency Hospital, A-2 Sarvodaya Nagar, Kanpur 208005

ARTICLE INFO

Article History:

Received 07th September, 2017
Received in revised form
22nd October, 2017
Accepted 10th November, 2017
Published online 30th December, 2017

Key Words:

Osseous Metaplasia,
Myeloid Metaplasia,
Chronic Pyelonephritis,
Infection, Inflammation.

ABSTRACT

Focal calcifications are common in kidney including both non malignant and malignant lesions. However, osseous metaplasia with bone marrow elements i.e., myeloid metaplasia is rare. In kidney myeloid metaplasia is reported in RCC. We, hereby report the first case of osseous and myeloid metaplasia in a patient of chronic pyelonephritis.

Copyright ©2017, *Deepti Gupta et al.* This is an open access article distributed under the Creative Commons Attribution License, which permits unrestricted use, distribution, and reproduction in any medium, provided the original work is properly cited.

Citation: Dr. Deepti Gupta, Dr. Anjali Tewari, Dr. Nupur Trivedi, Dr. Shefali Agarwal and Dr. Asha Agarwal, 2017. "Osseous and myeloid metaplasia in chronic pyelonephritis", *International Journal of Development Research*, 7, (12), 17849-17850.

INTRODUCTION

Osseous metaplasia is characterized by mature appearing bone in renal parenchyma. It is usually noted as a focal lesion in the cortex. It may vary in size and haematopoietic cells may be present in the larger lesions. In kidney both osseous and myeloid metaplasia are reported in Renal Cell Carcinoma and cases of allografts kidney. Osseous metaplasia is reported in chronic inflammatory/infectious lesions (Murugan *et al.*, 2008) We, hereby report the first case of osseous metaplasia with myeloid metaplasia in a patient of chronic pyelonephritis.

Case Report

A 36 year old male presented to the OPD with central abdominal pain and fever for last 2 months. USG showed gross left sided hydronephrosis with dilated ureter upto the pelvic brim. The CT also showed gross hydronephrosis and hydroureter. DTPA scan was done and it showed nonfunctioning left kidney.

***Corresponding author:** Dr. Deepti Gupta,
Consultant Pathologist, Regency Hospital, A-2 Sarvodaya Nagar,
Kanpur 208005, U. P

After the preoperative investigations, the patient underwent left nephrectomy and the specimen was received in the department of pathology. Gross examination revealed markedly dilated pelvicalyceal system with thinned out cortex and foci of calcification. Ureter was also markedly dilated. Microscopic examination revealed occasional sclerosed glomeruli with degenerative tubules filled with pink homogenous material. The interstitium showed dense lymphoplasmacytic inflammatory infiltrate and lymphoid aggregates. Multiple areas of osseous metaplasia with bone marrow elements were seen. (Figure 1 & 2) The PUJ and ureter also showed calcification. A histopathological diagnosis of chronic pyelonephritis with osseous and myeloid metaplasia was made.

DISCUSSION

Calcifications are common in both non malignant and malignant lesions of kidney, which include RCC, angiomyolipoma, intrarenal aneurysms, cystic kidney disease, chronic and Xanthogranulomatous pyelonephritis, schistosomiasis and tuberculosis (Bloom *et al.*, 2003).

This phenomenon appears to be non specific and most likely represents dystrophic calcification, seen in areas of fibrosis in nonneoplastic as well as neoplastic lesions. Osseous metaplasia in contrast to calcification is a rare entity in any organ. The unique feature of this case was presence of osseous metaplasia with myeloid metaplasia i.e., presence of bone marrow elements in the bony trabeculae in the renal parenchyma.

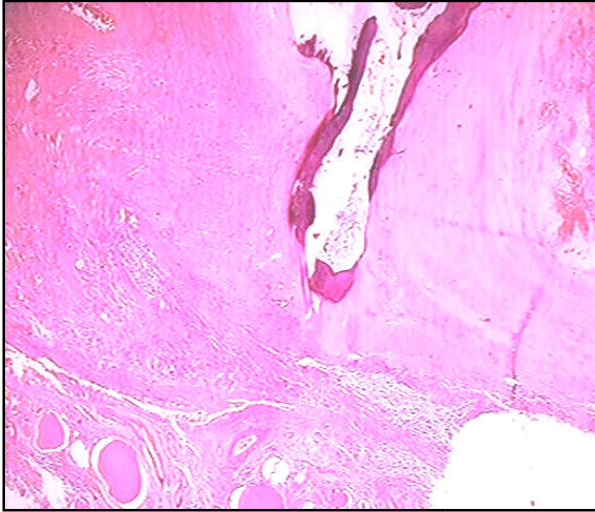


Figure 1. H and E stained section shows osseous metaplasia in chronic pyelonephritis (100x)

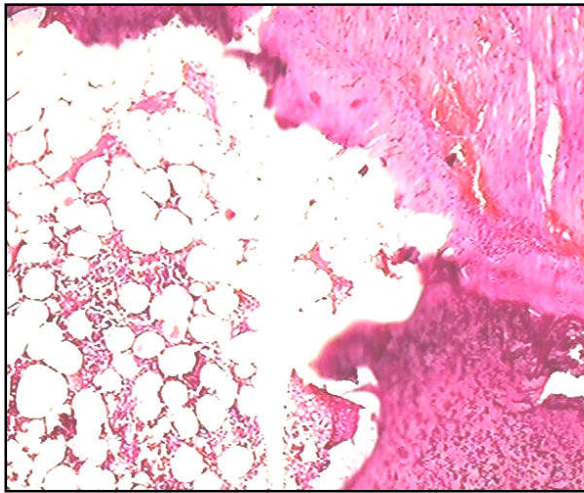


Figure 2. H and E stained section shows bone marrow elements in bony trabeculae in renal cortex (400x)

Osseous metaplasia with bone marrow elements has been reported in cases of RCC earlier but it has not been reported in a case of chronic pyelonephritis. Osseous metaplasia is seen as foci of eosinophilic osteoid and woven bone or the mineralized basophilic bone with interspersed lacunae. At times, the bone formed shows haematopoietic elements (myeloid metaplasia) (Ozkanli *et al.*, 2012). The pathogenesis of osseous metaplasia is unclear. Several hypotheses have been suggested, including a metaplastic or reparative reaction to necrosis and degenerative changes due to inflammation and tumour (Cribbs *et al.*, 1999).

It occurs as a response to injury or inflammation. These lesions occur when fibroblastic tissue is stimulated to form non-neoplastic bone or cartilage. New bone forms with or without a cartilage template and can be bordered by fibroblastic tissue. Foci of osseous metaplasia must be distinguished from metastatic osteosarcoma (Kefeli, 2007). In tumours, bone can be formed either by dedifferentiation of neoplastic cells into sarcomatous proliferation (osteosarcomatous component) or ossification of preexisting mucin or calcified focus (Haddad *et al.*, 1993) Yamasaki *et al* found bone morphogenetic protein 2 as an inducer of osteoblastic proliferation of pleuripotent cells in ossification (Yamasaki *et al.*, 2004). Meyer *et al* reported the role of IL-6 in the bone formation in a case of osseous metaplasia in DLBL in kidney (Meyer *et al.*, 2007). We, hereby report a unique case of renal osseous and myeloid metaplasia in a patient of chronic pyelonephritis. Long standing lesions can be associated with dystrophic calcification with both osseous and myeloid metaplasia.

REFERENCES

- Bloom TL, Gray Sears CL, Williams TR, Linfesty RL, Amling CL. 2003. Multilocular cystic renal cell carcinoma with osseous metaplasia in a 25 year old woman. *Urology*, 61(2):462.
- Cribbs RK, Ishaq M, Arnold M, O'Brien J, Lamb J, Frankel WL. 1999. Renal cell carcinoma with massive osseous metaplasia and bone marrow elements. *Annals of Diagn Pathol*, 3(5):294-9.
- Haddad FS, Shah IA, Manne RK, Costantino JM, Somsin AA.1993. Renal cell carcinoma insulated in the renal capsule with calcification and ossification. *Urologia Internationalis.*, 51(2):97-101.
- Kefeli M, Yildiz L, Aydin O, Kandemir B, Yilmaz AF. 2007. Chromophobe renal cell carcinoma with osseous metaplasia containing fatty bone marrow element: a case report. *Pathology Reseach and Practice.*, 203(10):749-52.
- Meyer P, Al-Masri H, Alkan S. 2007. Osseous Metaplasia in Diffuse Large B-Cell Lymphoma of the Kidney. *Am J Hematol.*, 82:321-4.
- Murugan P, Basu D, Manikandan R, Dorairajan LN, Kumar S. 2008. Osseous metaplasia in renal cell carcinoma: Report of a rare case. *Indian J Pathol Microbiol.*, 51:399-401.
- Ozkanli S, Yildirim A, Zemheri E, Keskin SK, Basok EK.2012. Osseous metaplasia and Bone Marrow Elements in a case of renal cell Carcinoma. *Case Reports in Urology* 2012;649257. doi:10.1155/2012/649257.
- Yamasaki M, Nomura T, Mimata H, Nomura Y. 2004. Involvement of bone morphogenetic protein 2 in ossification of renal cell carcinoma. *J Urol.*, 172:475-6.
