



ISSN: 2230-9926

Available online at <http://www.journalijdr.com>

IJDR

International Journal of Development Research
Vol. 07, Issue, 12, pp.17906-17911, December, 2017



ORIGINAL RESEARCH ARTICLE

OPEN ACCESS

IMPACT OF THE EXTENT OF CRANIECTOMY AND DURAPLASTY ON POST-OPERATIVE OUTCOME FOLLOWING DECOMPRESSIVE CRANIECTOMY FOR TRAUMATIC BRAIN INJURY

***Jothi Kumar Sethuraman and Aravinth Kumar Ashok**

Institute of Neurosurgery, Madras Medical College, Chennai – 03

ARTICLE INFO

Article History:

Received 17th September, 2017
Received in revised form
10th October, 2017
Accepted 14th November, 2017
Published online 30th December, 2017

Key Words:

Acute sdh,
Lobar contusions,
Decompressive craniectomy,
Duraplasty,
Post operative outcome.

ABSTRACT

Aim: To evaluate the impact of the size of decompressive craniectomy and duraplasty on the post operative outcome following decompressive craniectomy for traumatic brain injury.

Materials and Methods: This study was conducted at Institute of Neurosurgery, Madras Medical College. 136 patients, who underwent decompressive craniectomy for moderate and severe brain injury were included in the study. CT scan of brain showed Acute SDH, unilobar or multilobar contusions with diffuse cerebral edema, midline shift >5mm, and effacement of basal cisterns. Lax duraplasty using the temporalis fascia and pericranium was done in 20 patients. The size of the craniectomy defect was ascertained from post op CT Brain. The GCS and GOCS (Glasgow outcome score) at discharge were noted and outcomes were analyzed. Statistical analysis was performed by using MANOVA test. A statistically significant difference was indicated by a p-value of less than 0.05.

Results: Statistically significant favorable outcome was observed in patients who under went lax duraplasty and in those whom the size of the craniectomy defect was not less than 12 X 15 cm.

Conclusion: The study advocates that lax duraplasty and a craniectomy defect of not less than 12 x 15 cm will favorably influence the post op outcome.

Copyright ©2017, Jothi Kumar Sethuraman and Aravinth Kumar Ashok. This is an open access article distributed under the Creative Commons Attribution License, which permits unrestricted use, distribution, and reproduction in any medium, provided the original work is properly cited.

Citation: Jothi Kumar Sethuraman and Aravinth Kumar Ashok. 2017. "Impact of the extent of craniectomy and duraplasty on post-operative outcome following decompressive craniectomy for traumatic brain injury", *International Journal of Development Research*, 7, (12), 17906-17911.

INTRODUCTION

Decompressive Craniectomy

Traumatic brain injury (TBI) affects up to 2% of the population per year and constitutes the major cause of death and severe disability among young people (Ross Bullock, 2006). Road traffic injuries account for 2.1% of global mortality. The developing countries bear a large share of burden and account for about 85% of the deaths as a result of road traffic crashes. India accounts for about 10% of road accident fatalities worldwide (Arvind kumar, 2008). An injury to the brain may cause edema and produce swelling of brain. Cerebral edema can result from a combination of several

pathological mechanisms associated with primary and secondary injury patterns in traumatic brain injury (TBI) (Juan Sahuquillo, 2009). As pressure within the skull increases, brain tissue displacement can lead to cerebral herniation, resulting in disability or death (Ross Bullock, 2006; Arvind kumar, 2008; Abhishek Patro, 2009). Surgical removal of a portion of the skull, known as decompressive craniectomy (DC), has been performed for the purpose of relieving elevated intracranial pressure with outcome improvement in specific TBI patients (Rosner, 1995 and Enevoldsen, 1978). Most of the debate surrounding the role of decompressive craniectomy in the management of severe TBI results from a paucity of data coming from randomized controlled trials (RCTs) assessing this intervention (Abrar, 2009; Kocher, 1902 and Kjellberg, 1971). There have been variations in surgical techniques, timing, and patient populations in most of the observational studies published in the last 2 decades (Kocher, 1901; Kjellberg, 1971; Britt, 1978 and Cooper, 1976). A large

***Corresponding author: Jothi Kumar Sethuraman**
Institute of Neurosurgery, Madras Medical College, Chennai – 03

frontotemporoparietal DC (not less than 12 x 15 cm or 15 cm diameter) is recommended over a small frontotemporoparietal DC for reduced mortality and improved neurologic outcomes in patients with severe TBI.

Types of surgical decompression

- Primary decompressive craniectomy (P-DC) or Prophylactic decompression is defined in this review as any surgical decompression performed, with or without brain tissue removal, in patients undergoing surgery primarily for the evacuation of any type of intradural lesion. The aim of prophylactic craniectomy is not only to control refractory ICP but also to avoid expected postsurgical increases in ICP. In these procedures the decision taken by the surgeon is generally independent of ICP and is usually based on a CT scan or intraoperative surgical findings (brain swelling, a 'tight' brain, or difficulties in repositioning the bone flap), or both (Britt, 1978 and Cooper, 1976).
- Secondary decompressive craniectomy (S-DC) or Therapeutic decompression is defined as the procedure performed in patients in whom continuous ICP monitoring is conducted and in whom high ICP is refractory to medical treatment. This therapeutic option is used in some centers after first- or second- line therapeutic measures have failed to control ICP. In the category of S-DC we also included patients who had undergone a first surgical procedure to evacuate a space-occupying lesion and who had later developed delayed massive unilateral or bilateral brain swelling. Although previous surgery might have been performed in these patients, the purpose of surgical decompression is to control high ICP (Guerra, 1999a).

The mechanism by which decompressive craniectomy provides reliefs in raised ICP are (Abrar, 2009).

- It lowers the ICP immediately.
- It adds vector of expansion to cerebral hemispheres which relieves brain herniation.
- Allows exploration of subdural space.
- In addition, it provides quick tapering of medical treatment, in order to avoid potential complications.

Effects of Decompressive Craniectomy

- Improving cerebral perfusion
- Preventing ischemic damage
- Avoiding mechanical compression of the brain (brain herniation)

The overall effects of decompressive craniectomies are to increase volume-buffering capacity of the cranial vault by allowing for centripetal herniation. The centripetal herniation in turn minimizes centrifugal compression of the brain stem structures (Clark chen, 2006). Decompressive craniectomy reduces intracranial pressure by 50%, duratomy further enhances intracranial pressure reduction by an additional 35% (Yoo, 1999). The rationale for decompressive surgery is based on the Monro-Kellie law. According to this theory intracranial volume should remain constant and volumetric compensations should be achieved by shifts in CSF, cerebral blood volume, or brain herniation. Removing a variable amount of bone, with or without leaving the duramater open or augmented by a

duraplasty, is a fast and effective means of increasing intracranial volume; reducing elevated intracranial pressure and increasing the compliance of the intracranial space. In the Aarabi *et al* study, mean ICP decreased from 24 to 14.6 mm Hg after decompressive craniectomy (Aarabi, 2006).

AANS Recommendations

The American Association of Neurological Surgeons has recommended decompressive craniectomy for patients with traumatic brain injury and refractory intracranial hypertension if some or all of the following criteria were met (Abrar, 2009)

- Diffuse cerebral swelling on CT imaging.
- Within 48 hrs. of injury.
- No episodes of sustained intracranial hypertension (ICP) > 40 mm Hg before surgery.
- GCS > 3 at some point subsequent to injury.
- Secondary clinical deterioration, and
- Evolving cerebral herniation syndrome.

Indications for Decompressive Craniectomy

- DC has most commonly been performed in patients with traumatic brain injury and cerebral infarction associated with intractable intracranial hypertension.
- Other indications, which have mostly been described in single case reports or small case series includes aneurysmal SAH, ICH, palliation for brain tumors, meningitis, subdural empyema, encephalitis, acute disseminated encephalomyelitis, encephalopathy due to Reye syndrome, toxoplasmosis, and cerebral venous and dural sinus thrombosis (Peter Hutchinson, 2007 and Clark chen, 2006).

Surgical Technique

Wide variability has been reported in the surgical procedures for performing decompressive surgery. Nine different types of craniectomies were reported. These variations include small to massive amounts of bone removal, unilateral or bilateral bone decompression, opening the duramater or leaving it closed, scarifying the duramater to decrease its rigidity, and sectioning of the falx among others. Localization of bone removal can be unilateral, bilateral, bifrontal, or sub temporal; or it can be expanded to what has been called 'circumferential decompression'.

In general, these decompression techniques can be divided into three approaches (Clark Chen, 2006)

Fronto-temporo-parietal approach, frontal approach and temporal approach. All the three approaches can be performed unilaterally or bilaterally.

Fronto-temporo-parietal approach

The patient is placed in supine with head elevated and rotated 30 to 45 degrees. Vertex of the head is directed downwards to bring the zygomatic arch to the uppermost plane. The skin incision can be in the form of trauma flap, with the goal of exposing the following margins of craniectomy: anteriorly to the superior border of orbital roof (avoiding entry into frontal sinus); posteriorly to at least 2cm lateral to the external auditory meatus; medially to 2cm lateral to midline (avoiding

sagittal sinus); and inferiorly to the floor of middle cranial fossa. Temporalis muscle is reflected anteriorly. Burr holes are placed at the keyhole, the root of the zygoma and along the planned craniectomy margin, and these are connected. The sphenoid wing is fractured and removed to the superior orbital fissure. The dural edges are tacked up to bony margin and dura is opened in a stellate manner.

Duraplasty

Currently, decompressive craniectomy combined with augmentative duraplasty is widely performed and is recommended by most authors (Piek, 2000 and Winn, 2003). The temporary removal of a piece of skull followed by loose closure of the dura and skin layers presumably allows for expansion of the edematous brain into a duratomy "bag" under the loosely closed scalp without restriction by the hard skull; the dura would also protect the underlying brain tissue with prevention from over cephalocele. Yang *et al.* found that the patients who underwent decompressive craniectomy combined with initially augmentative duraplasty had better outcomes and lower incidences of secondary surgical complications (such as hydrocephalus, subdural effusion, and epilepsy) compared with those who only underwent surgical decompression, leaving the dura open (Yang, 2003). At present, large decompressive craniectomy combined with enlargement of the dura by duraplasty is used by most research groups and seems to have the most favorable results. Several prospective studies have agreed that the procedure of decompressive craniectomy with simultaneous augmentative duraplasty would also be able to control refractory intracranial hypertension and play a beneficial role in patients with severe TBI. Coplin *et al.* performed a prospective trial on the feasibility of craniectomy with duraplasty versus "traditional craniotomy" as a control group in patients who developed brain swelling, and found that despite more severe head trauma, the patients in the study group had similar outcomes to the control group (Coplin, 2001). Ruf *et al.* performed decompressive craniectomy and simultaneous dural augmentation with duraplasty in six children whose elevated ICPs could not be controlled with maximally intensified conservative therapies. Subsequently, the ICP normalized, with improved outcomes after the procedure.¹⁹ Figaji *et al.* reported prospective studies on 12 patients who had undergone decompressive craniectomy with augmentative duraplasty. In this case series, the mean ICP reduction was 53.3% and clinical improvement as well as reversion of radiographic data was attained in most patients (11/12); all 11 survivors had good outcomes (GOS 4 or 5) (Fagiji, 2006). Additionally, several other pathological indices improved after this combined procedure, including cerebral blood perfusion and cerebral oxygen supply (BOR-SENG-SHU Edson, 2004; Fagiji, 2007). These results showed that large decompressive craniectomy combined with augmentative duraplasty has favorable decompressive effects in the treatment of traumatic refractory intracranial hypertension compared with surgical decompression with dura opening. However, no well-planned study has compared the two methods, and in many centers, decompressive craniectomy with complete dura opening is still performed routinely. Two main methods are used for dural augmentation with duraplasty: the dura is enlarged with the patient's own tissue, such as temporal fascia, temporal muscle, or galea aponeurotica (Yang, 2003; Guerra, 1999; Yu, 2006), or this is performed with artificial or xenogeneic tissue, such as artificial dura substitute or bovine pericardium (Coplin, 2001; Fagiji, 2006).

The method using temporalis fascia is similar to the one introduced by Yu *et al.* (Yu, 2006). They separated the temporal deep fascia from the temporalis muscle to the zygomatic arch, and then cut the fascia from the base backwards along the zygoma but left the fascia base 1-2 cm long for the blood supply. Finally, they turned the temporal fascia beneath the temporal muscle and sutured it to the dura. They performed this method in 36 patients, and 33 survived. Generally, temporal deep fascia is large enough for the enlargement of dura in during decompressive craniectomy, and forms a pedicle of temporal fascia that maintains the blood supply.

Aim of the Study

This study was undertaken to assess the influence of the size of craniectomy and lax duraplasty on the post operative outcome and survival following decompressive craniectomy for traumatic brain injury.

MATERIALS AND METHODS

It is an analytical study conducted at the Institute of Neurosurgery, Madras Medical College and Rajiv Gandhi Government General Hospital, Chennai. All Patients admitted in our hospital trauma ward with moderate to severe head injury who are undergoing primary decompressive craniectomy according to brain trauma foundation guidelines are included in this study. Categorization of head injury severity is based on Glasgow coma scale (GCS) score, GCS 9-13=moderate, GCS 3-8=severe.

Inclusion criteria

- Age 12-70 years and within first 48 hrs. from time of injury.
- Only traumatic causes.
- Post resuscitation GCS 4-13.
- CT scan with evidence of Acute SDH, unilobar or multilobar contusions with diffuse cerebral edema, midline shift >5mm, and effacement of basal cisterns.

Exclusion Criteria

- Age less than 12 years and more than 70 years.
- Nontraumatic causes like infarct, spontaneous ICH or aneurysmal bleed.
- Post resuscitation GCS 3.
- Bilateral fixed and dilated pupils.
- Absent brain stem reflexes.
- Devastating injury not expected to survive for 24 hrs.
- Patients who are not willing for surgery or study.

A CT scan was done as soon as possible. Patients with moderate to severe head injury requiring decompressive craniectomy considered for this trial, entry will be determined using the above inclusion and exclusion criteria after resuscitation, and data were entered in proforma. Consent for surgery and study was obtained from next of kin after detail explanation about the study. Approval for the study was obtained from the ethics committee. After the surgery patient treated in head injury ICU, then CT scan brain was done with in 24hr to 48 hrs. and compared to pre op CT scan. The postoperative GCS and GOCS (Glasgow outcome score) at

discharge from the hospital were noted, primary and secondary outcomes were analyzed.

Lax duraplasty was done using temporalis fascia and pericranium harvested during surgery.

The size of craniectomy was assessed in the post op period with CT – Brain.

Primary outcome measures

- Proportion (%) of favourable outcomes (GOCS4&5), unfavourable outcome (GOCS1,2&3)
- Secondary outcome measures:
- Assessing post op GCS, adequacy of bone removal, reduction of mid line shift, basal cisterns compression, residual hematomas in post op CT scan and complications.

RESULTS

Size of Craniectomy

From the 136 patients included in the study, 126 patients underwent an adequate craniectomy of size 12 x 15 cm.10 patients did not have an adequate craniectomy (size less than 12 x 15cm).

Table 1. Bone removal distribution

Bone Removal	No of patients
Adequate	126
Inadequate	10
Total	136

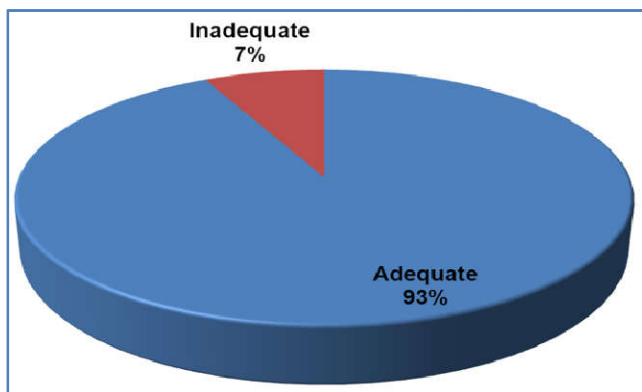


Fig. 1. (Bone removal distribution)

Out of the 126 patients who underwent adequate craniectomy, 49 patients had favourable outcome and 77 patients had unfavorable outcome. Of the 10 patients who underwent inadequate craniectomy none had a favourable outcome.

Table 2. Bone removal vs. outcome

Bone Removal	No of patients		Total
	Favourable Outcome	Unfavourable Outcome	
Adequate	49	77	126
Inadequate	0	10	10
Total	49	87	136

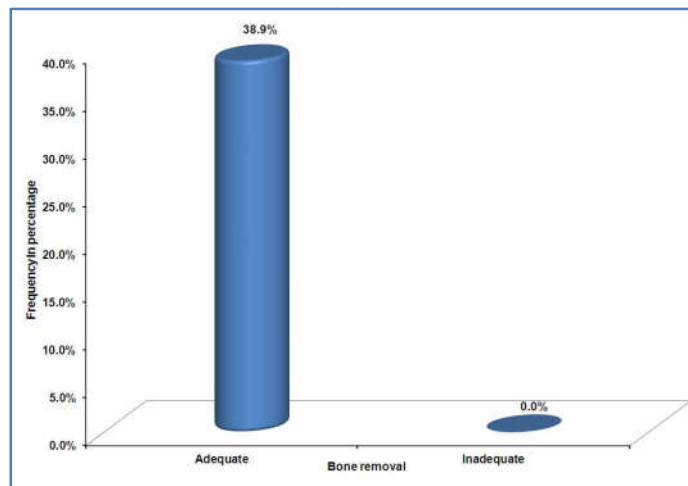


Fig. 2. Percentages of favourable out come

There is statistical significance between Adequate Bone removal and outcome (P-value – 0.009 < 0.05) From the 126 patients who had adequate craniectomy, 56 patients survived and the remaining 70 expired. All the 10 patients who had inadequate craniectomy expired.

Table 3. Bone removal Vs. Survival / Death

Bone Removal	No of patients		Total
	Survival	Death	
Adequate	56	70	126
Inadequate	0	10	10
Total	56	80	136

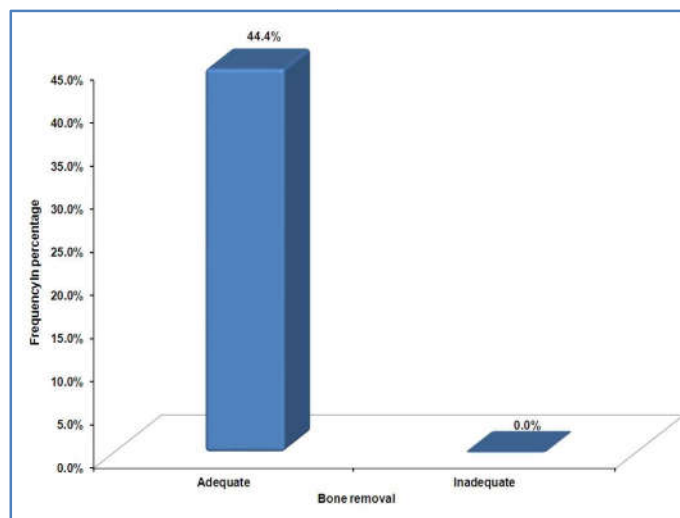


Fig. 3. Percentage of survival)

There is significant statistical difference between Bone removal and survival (P-value – 0.006 < 0.05)

Duraplasty

Out of the 136 patients who were included in the study, 20 underwent lax duraplasty. 116 patients did not undergo duraplasty.

Table 4. Duraplasty distribution

Duraplasty	No of patients
Not done	116
Done	20
Total	136

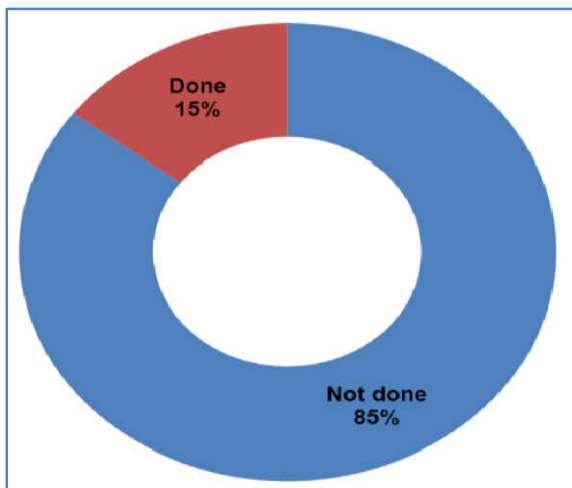


Fig. 4. Duraplasty Distribution

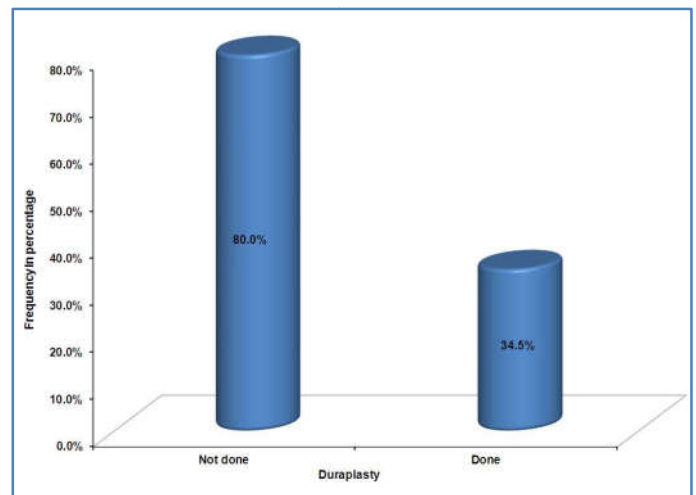


Fig. 6. Percentage of Survival

From the 20 patients who underwent lax duraplasty, 16 patients had favourable outcome and 4 patients had unfavourable outcome. From the 116 patients who did not undergo duraplasty, 33 patients had favourable outcome and 83 patients had unfavourable outcome.

Table 5. Duraplasty vs. outcome

Duraplasty	No of patients		Total
	Favourable Outcome	Unfavourable Outcome	
Done	16	4	20
Not done	33	83	116
Total	49	87	136

There is statistical difference between Duraplasty and survival (P-value – 0.000 < 0.05)

DISCUSSION

This study of ours considered two criteria to assess the post operative outcome following decompressive craniectomy for traumatic brain injury.

Adequacy of bone removal

DC creates a window through which brain tissue under direct mechanical compressive forces can protrude. ICP reduction varies from 15 to 70 % after DC. Munch *et al* calculated the gained volume after DC to be between 15.9 and 347.4 cm³, with a median volume of 73.6 cm³. Obviously, the larger the DC, the more effective ICP reduction will be¹⁷. In our study, inadequate bone removal patient had 100% mortality. Favourable outcome was better among adequate bone removal patient (38.9%).

Duraplasty

Duraplasty at the time of decompression has been observed to lower the incidence of subdural effusion. Augmentation of craniectomy with duraplasty has been suggested as a mechanism to prevent or limit external cerebral herniation. Techniques of lattice duraplasty have also been suggested to limit external cerebral herniation. In our present study patient with duraplasty had better favourable outcome (80%), only 15% percentage of patients underwent duraplasty (15%). These results are in coherence with guidelines given by the Brain Trauma Foundation and with most of the studies conducted on decompressive craniectomy.

Conclusion

Our study concludes that the decompressive craniectomy size of 12 x 15 cm (as suggested by the Brain Trauma Foundation guidelines) and a lax duraplasty following decompressive craniectomy have a statistically significant positive influence on the post operative outcome and survival following decompressive craniectomy for Traumatic Brain Injury.

REFERENCES

Aarabi B *et al*. 2006. Outcome following decompressive craniectomy for malignant swelling due to severe head injury. *J Neurosurgery*, 104; 469-79.

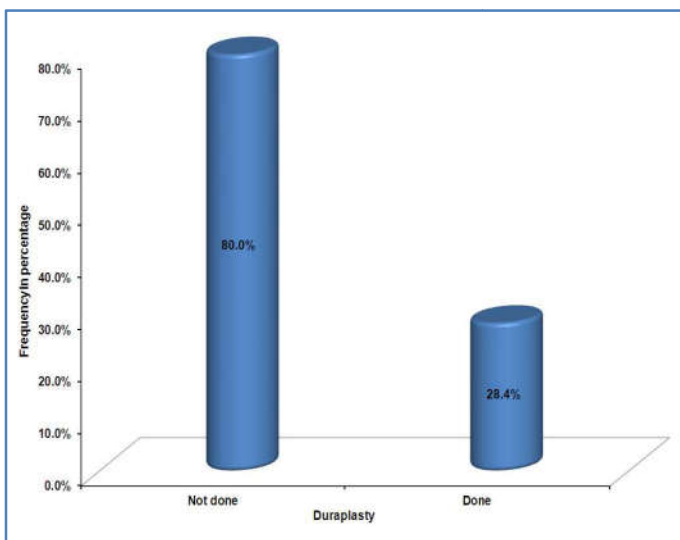


Fig. 5. Percentages of favourable outcome

There is statistical significant difference between Duraplasty and outcome (P-value – 0.000 < 0.05). From 20 patients who underwent lax duraplasty, 16 patients survived and 4 patients expired. Out of 116 patients who did not undergo duraplasty, 40 patients survived and 76 patients expired.

Table 6. Duraplasty vs. Survival / Death

Duraplasty	No of Patients		Total
	Survival	Death	
Done	16	4	20
Not done	40	76	116
Total	56	80	136

- Abhishek Patro, Sureswar Mohanty. 2009. Pathophysiology and treatment of traumatic brain edema. *Indian journal of neurotrauma*, vol 6; No1; 11-16.
- Abrar A Wani *et al.* 2009. Decompressive craniectomy in head injury. *Indian journal of neurotrauma*; vol 6; No1 ;103-110.
- Arvind Kumar *et al.* 2008. Fatal road traffic accidents and their relationship with head injury; An epidemiological survey of five years. *Indian journal of neurotrauma*; vol 5; No2; 63-67.
- BOR-SENG-SHU Edson, TEIXEIRA *et al.* 2004. Transcranial doppler sonography in two patients who underwent decompressive craniectomy for traumatic brain swelling: report of two cases. *Arq. Neuro-Psiquiatr.* 62:715-721
- Britt, R.H., Hamilton, R.D. 1978. Large decompressive craniectomy in treatment of acute subdural haematoma. *Neurosurgery*, 2;195-200.
- Clark Chen *et al.* 2006. Decompressive craniectomy: Physiologic rationale, clinical indications, and surgical consideration. Operative neurosurgical techniques, Schmidek Elsevier; 70-80.
- Cooper PR *et al.* 1976. Hemispheric craniectomy in the treatment of acute subdural hematoma; A re-appraisal. *Surgical Neurology*, 5;8-25.
- Coplin WM, Cullen NK, Policherla PN. 2001. Safety and feasibility of craniectomy with duraplasty as the initial surgical intervention for severe traumatic brain injury. *J Trauma.*, 50:1050-1059
- Enevoldsen, E.M., Jensen, F.T. 1978. Autoregulation and CO₂ responses of cerebral blood flow in patients with acute severe head injury. *J Neurosurgery.*, 48; 689-703.
- Fagiji, A.A., Fieggen, A.G., Sandler, S.J. 2007. *et al.* Intracranial pressure and cerebral oxygenation after decompressive craniectomy in a child with traumatic brain swelling. *Childs Nerv Syst.* 2007Nov;23(11):1331-5
- Fagiji, A.A., Fieggen, A.G., Argent, A. *et al.* 2006. Surgical treatment for "Brain compartment syndrome" in children with severe head injury. *S Afr Med J.*, 96:969-975
- Guerra *et al.* 1999a. Decompressive craniectomy to treat intracranial hypertension in head injury patients. *Intensive care medicine.* 25;1327-9.
- Guerra WK, Gaab MR, Dietz H. *et al.* 1999. Surgical decompression for posttraumatic brain swelling: indications and results. *J Neurosurg.* 90:187-196
- Huang, Q, Dai, W.M., Wu, T.H. *et al.* 2003. Comparison of standard large trauma craniotomy with routine craniotomy in treatment of acute subdural hematoma. *Chin J Traumatol.* 6:305-308
- Juan Sahuquillo. 2009. Decompressive craniectomy for the treatment of refractory high intracranial pressure in traumatic brain injury. *The Cochrane Library*, Issue 2; 1-13.
- Kjellberg RN, Prieto A Jr; Bifrontal decompressive craniectomy for massive cerebral edema. *J Neurosurgery* 34; 1971,488-493.
- Kocher T; Die Therapie des Hirndruckes, Holder A(ed); Hirnerschutterung, Hirndruckes. Vienna; A Holder, 1901, 262-266.
- Mitchell *et al.* Decompressive craniectomy with lattice duraplasty. *Acta Neurochir* 146;159-160;2004
- Munch *et al.* , Management of severe traumatic brain injury by decompressive craniectomy. *Neurosurgery* 47;2000; 315-322.
- Peter Hutchinson *et al.* Surgery for brain edema. *Neurosurg focus* 22; 2007;E14.
- Piek J. Decompressive surgery in the treatment of traumatic brain injury. *Curr Opin Crit Care.* 2000;17:451-533
- Rosner MJ, Rosner MD. Cerebral perfusion pressure; Management protocol and clinical results. *J Neurosurgery* 1995; 83; 949-62.
- Ross Bullock M *et al.* Guidelines for field management of combat-Related head trauma. Tom Knuth *et al.*, brain trauma foundation; volume 58; number 3; march 2006; 1-52.
- Ruf B, Heckmann M, Schroth I. *et al.* Early decompressive craniectomy and duraplasty for refractory intracranial hypertension in children: results of a pilot study. *Crit Care.* 2003; 7:R133-138
- Winn HR. Youmans Neurological Surgery; 5th ed. Philadelphia Pennsylvania: WB Saunders Co. 2003
- Yang XJ, Hong GL, Su SB. *et al.* Complications induced by decompressive craniectomies after traumatic brain injury. *Chin J Traumatol.* 2003;6:99-103
- Yoo *et al.* Ventricular pressure monitoring during bilateral decompression with dural expansion. *J Neurosurgery*; 1999;91; 953-9.
- Yu HT, Wang B, Xia JG. *et al.* The application of turning down the deep temporal fascia to mend the dura mater in the operation of intracranial supratentorial decompression in skull trauma. *Chin J Neuromed (In Chinese).* 2006; 5:937-939
