



ORIGINAL RESEARCH ARTICLE

OPEN ACCESS

UNILATERAL TEMPOROMANDIBULAR JOINT ANKYLOSIS ALONG WITH BILATERAL HIP JOINT DYSPLASIA: A CASE REPORT

***Dr. Debasish Pramanick and Dr. Sandip Ghose**

Dept. of Oral Pathology, Dr. R. Ahmed Dental College and Hospital, Kolkata, 700014, India

ARTICLE INFO

Article History:

Received 09th November, 2017
Received in revised form
08th December, 2017
Accepted 23rd January, 2018
Published online 28th February, 2018

Key Words:

TMJ Ankylosis,
Hip joint Dysplasia.

ABSTRACT

Temporomandibular joint (TMJ) ankylosis may be defined as a fibrous or bony union of the complex of articular disc and bony condyle along with the glenoid fossa of temporal bone resulting in restricted mandibular movements. It may manifest unilaterally or bilaterally. Hip joint dysplasia is also another orthopaedic complication resulting in looseness and general instability of the hip joint. Co-existence of these two lesions is very rare and probably this case is the first of its kind as far as the literature review is available till date. There lies the importance of this case.

Copyright © 2018, Dr. Debasish Pramanick and Dr. Sandip Ghose. This is an open access article distributed under the Creative Commons Attribution License, which permits unrestricted use, distribution, and reproduction in any medium, provided the original work is properly cited.

Citation: Dr. Debasish Pramanick and Dr. Sandip Ghose, 2018. "Unilateral temporomandibular joint ankylosis along with bilateral hip joint dysplasia: A case report", *International Journal of Development Research*, 08, (02), 19094-19096.

INTRODUCTION

Temporomandibular joint (TMJ) ankylosis may be defined as a union of the complex of articular disc and bony condyle along with the glenoid fossa of temporal bone resulting in restricted mandibular movements. It may manifest unilaterally or bilaterally. This ankylosis may be either fibrous adhesion or bony fusion of the TMJ complex. It is a serious disability condition that may cause problems in mastication, digestion, speech, appearance and hygiene. TMJ Ankylosis, a serious disability condition, can affect chewing, aesthetics, hygiene, speech and often lead behavioural alteration (Aggarwal *et al.*, 1990). Commonly encountered causes of TMJ ankylosis are – trauma, infection, ankylosing spondylitis and sometimes TMJ surgery (Row, 1982). The hip joint, one of the most important weight bearing joint of the body, is composed of the femoral head (Ball) which fits into the acetabulum (Socket) and is held tightly in place by the surrounding ligaments and joint capsule. Hip joint dysplasia is also another orthopaedic complication resulting in looseness and general instability of the hip joint. Severity of hip joint dysplasia may be either subluxation or low dislocation or high dislocation. Dysplastic hip joint may be unilateral or bilateral.

*Corresponding author: Dr. Debasish Pramanick,
Dept. of Oral pathology, Dr. R. Ahmed Dental College and Hospital,
Kolkata, 700014, India.

Co-existence of TMJ ankylosis and hip joint dysplasia is a very rare and is probably the first reported case of its kind.

MATERIALS AND METHODS

A 14-year-old boy reported to the Department of Oral Pathology, Dr. R. Ahmed Dental College and Hospital, Kolkata with a complaint of compromised aesthetics due to facial asymmetry, decreased mouth opening and difficulty in chewing since last one year. Patient was apparently well last one year back. Then he noted a slow deviation of the chin towards right side resulting in facial asymmetry. Mouth opening also started decreasing and patient encountered difficulty in chewing food. Before examination of the patient, history was recorded after verbal questionnaires to the patient and his mother. Past history revealed a blunt injury to the occipito-temporal region of the foetus during normal delivery. Injury resulted in slow and diffuse swelling in the head neck region of the neonate. Personal history of the patient was nothing significant. Family history suggested that the patient had twin sisters – one of them being normal and the other had a history of seizures, defective speech and difficulty in walking but without any growth retardation. Parents of the patient had neither a history of consanguinity nor a physical and mental debilitating illness. General survey of the patient showed

average built with difficulty in walking and mild tenderness over hip joint bilaterally. Extraoral orofacial examination revealed deviated chin towards right side along with right sided facial fullness and left sided facial depression. No evidence of scar mark noted. On palpation, mandible and maxilla was non-tender along with restricted TMJ movement. Regional lymph nodes were non-palpable. During intraoral examination, there was deviation of the mandible towards right side on mouth opening. Interincisal distance, being 21 mm, suggested of restricted mandibular depression. Full complement of teeth was present. Tongue movement was normal. Oral mucosa was nil of note. Cone Beam Computed Tomography (CBCT) reconstructed view of the jaws showed altered morphology of right condyle which appears to be attached with glenoid fossa. Right sided glenoid space was also not appreciable. There was also marked deepening of antegonial notch. Compensatory enlargement of right side coronoid process was also evident which was suggestive of coronoid hyperplasia. Left side condyle and coronoid appeared to be normal with prominent glenoid space. Midline shifted towards right with flaring of both upper and lower anterior teeth. Overall view suggested Unilateral TMJ ankylosis of right side.

Pelvic radiography revealed resorption of right femoral head. Bilateral hip joint dislocation along with pseudo arthrosis on left side was also noted. Acetabulum was dysplastic and shallow bilaterally. Overall impression suggested Developmental Dysplasia of Hip (DDH). Complete haemogram was within normal limits. Alkaline phosphatase level in blood was within normal range (180U/L), but Acid phosphatase was elevated (5.8 IU/L). Serum calcium was also monitored and found to be within normal range (9.5 mg/dl). After overall physical examination and necessary investigations, the case was provisionally diagnosed to be of Unilateral TMJ ankylosis with associated bilateral Developmental Dysplasia of Hip. The patient was referred to the Department of Oral Surgery and Orthopaedics for necessary treatment of TMJ and hip joint respectively.

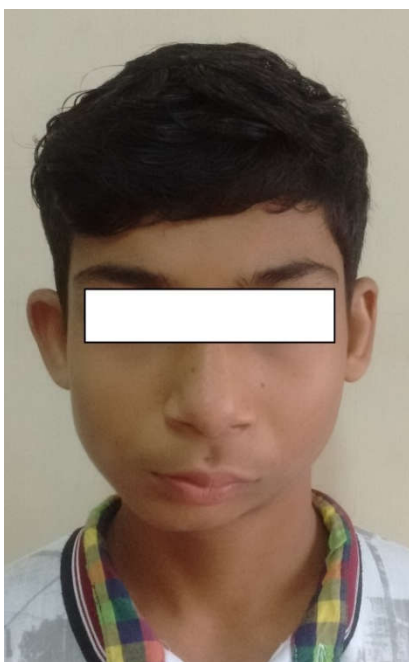

Figure 1. Frontal profile of the patient showing deviated chin towards right side with facial fullness in the right side

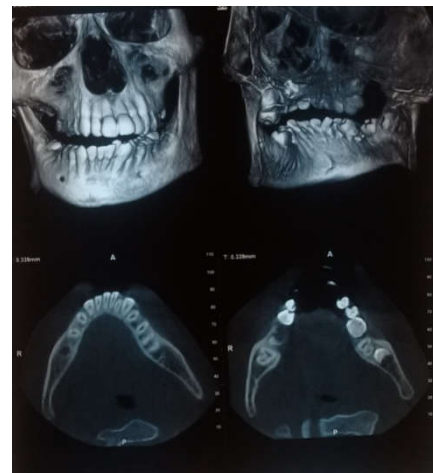


Figure 2. CBCT of maxilla and mandible (axial section)

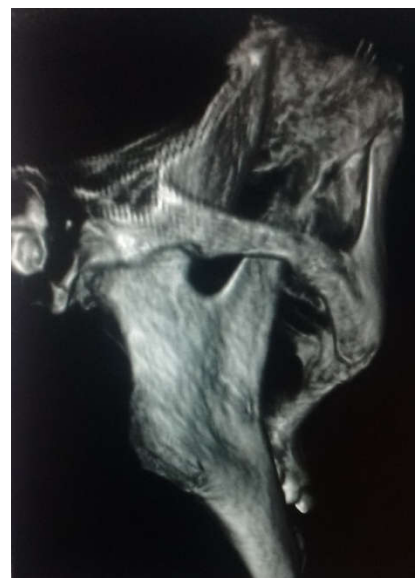

Figure 3. CBCT Reconstructed view showing right condylar ankylosis, obliterated joint space, elongated coronoid process and prominent antegonial notch

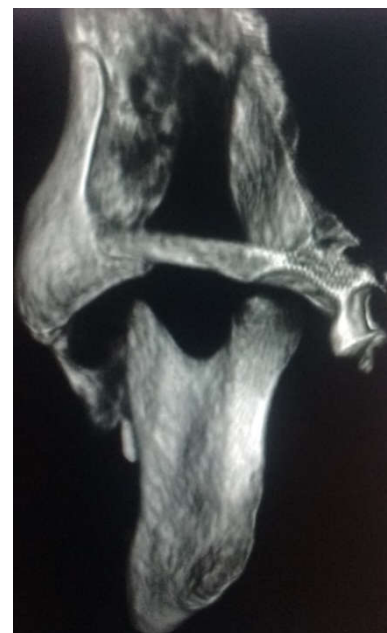

Figure 4. CBCT Reconstructed view showing left condyle which is normal in morphology and joint space can be appreciated

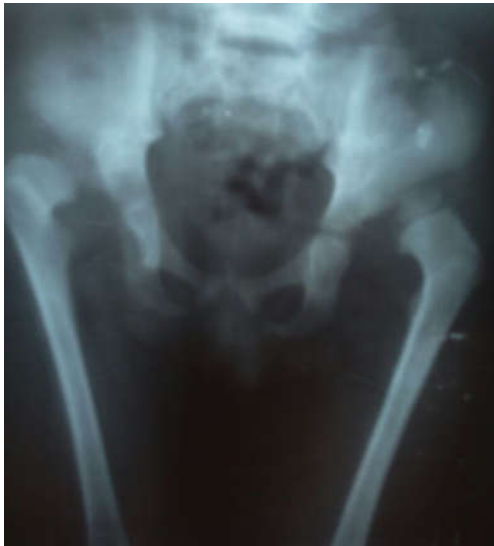

Figure 5. Pelvis radiography showing bilateral hip joint dysplasia

DISCUSSION

Unilateral TMJ ankylosis can be diagnosed with the following clinical findings such as displacement of chin laterally and backward towards affected side, deviation of chin towards ankylosed side, elongated coronoid process and prominent antegonial notch towards affected side (Shafer *et al.*, 2006). TMJ ankylosis can be classified on the basis of site of involvement (intra articular or extra articular), type of union (either bony or fibrous or fibro-osseous) and the grade or degree of union (complete or incomplete). It can also be classified into Type I, where the condyle is present together with fibrous adhesions. In case of Type II, there is bony fusion, together with condylar remodelling, but the medial pole remains intact. Type III, is an ankylotic block and the ramus is fused with zygomatic arch, but the medial pole stays intact. And in Type IV the ramus is fused to the skull base due to true ankylotic block (Silver *et al.*, 1977). Unilateral TMJ ankylosis have various differential diagnosis associated with the similar clinical presentation and they are Hemifacial macrosomia, Goldenher syndrome, Hallerman–Streiff Syndrome, Condylar tumor. In case of Hemifacial macrosomia, besides developmental anomaly of TMJ, there is underdevelopment of masticatory muscle sear with associated hearing loss and cardiac anomalies. Unilateral TMJ ankylosis don't present with hearing loss, underdeveloped ear and cardiac complications (Gorlin *et al.*, 2001). Goldenher syndrome, also known as oculoauriculovertebral syndrome (Shafer *et al.*, 2006), is the most severe form of hemifacial microsomia.

There is also presence of eye tumours, fused spine unlike Unilateral TMJ ankylosis. Dyscephalia, bird facies, hypoplastic mandible/ ramus, missing condyle, cataract, microphthalmia, skin atrophy, dental anomalies are the clinical findings associated in Hallerman–Streiff syndrome. Such features are usually absent in Unilateral TMJ ankylosis. Another important differential diagnosis includes Condylar tumor. But, a history of trauma or injury, other types joint diseases, local or systemic infection may help the clinician to rule out the idea of Condylar tumor. Now, as far as the treatment of TMJ ankylosis is concerned, it may include simple gap arthroplasty, interpositional arthroplasty and total joint replacement with a prosthesis. During surgical treatment in children, the potential for further growth should always be kept in mind prior to chalking out of treatment plan (Roychoudhury *et al.*, 1999). In case of management of hip joint dysplasia, ideally at this age of the patient i.e 14-year-old, it should be kept as it is until and unless it causes acute problems like severe pain during walking. If it is too painful at this age, then hip relocation may be an option. Otherwise, at a later age, the patient will need hip joint replacement surgery. So, it can be concluded that a case of unilateral TMJ ankylosis along with bilateral dysplasia of hip joint is a very rare of its kind and is not reported previously as far as our knowledge through literature study is concerned.

Acknowledgement – None

REFERENCES

- Aggarwal, S., Mukhopadhyaya, S., Berry, M. and Bhagore, S. 1990. Bony ankylosis of the temporomandibular joint. A computed tomographic study oral surg, oral med, *oral patho*, 69: 128-132.
- Gorlin, R.J., Cohen, M.M. and Hennekan, R.C. 2006. Syndromes of Head and Neck. 4th edition. New York: Oxford University Press; 2001. Shafer, Hine, Levy. Shafer's Textbook of Oral Pathology 5thEdn ; R Rajendran, B Sivapathasundaram, pp – 987
- Row, N.C. 1982. Ankylosis of the temporomandibular joint. *J. Roy Coll Edinb*, 67: 96-99.
- Roychoudhury, A., Parkash, H. and Trikha, A. 1999. Functional restoration by gap arthroplasty in temporomandibular joint ankylosis: A report of 50 cases. *Oral Surg Oral Med Oral Pathol Oral Radiol Endod*, 87:166-9.
- Shafer, Hine, Levy. 2006. Shafer's Textbook of Oral Pathology 5thEdn ; R Rajendran, B Sivapathasundaram pp– 1014.
- Silver, C.M., Motomed, M. and carlothi, A.E. 1977. Arthroplasty of the temporomandibular joint with use of vitalium condyle prosthesis *J. oral surgery*, 35:909-913
