

## A MORPHOMETRIC STUDY OF MANDIBULAR FORAMEN AND ACCESSORY MANDIBULAR FORAMINA IN ADULT HUMAN MANDIBLES AND ITS CLINICAL IMPLICATIONS

\*Dr. Amita Sarkar

K. P. C. Medical College & Hospital Under West Bengal University of Health Sciences

### ARTICLE INFO

#### Article History:

Received 17<sup>th</sup> July, 2018  
Received in revised form  
26<sup>th</sup> August, 2018  
Accepted 09<sup>th</sup> September, 2018  
Published online 30<sup>th</sup> October, 2018

#### Key Words:

Mandibular Foramen,  
Accessory mandibular foramen,  
Mandibular ramus, inferior  
Alveolar nerve block.

### ABSTRACT

**Introduction:** The mandibular foramen (MF) is an important anatomical landmark for procedures like inferior alveolar nerve block, implant treatment and mandibular osteotomies. Accessory mandibular foramina (AMFs) may act as a route for spread of infection and tumour cells. **Methods:** 50 adult human mandibles were studied irrespective of age and sex. The position of MF was recorded in relation to various landmarks on mandibular ramus and presence of AMFs were noted on both sides. **Results:** The mean distance of MF from anterior border of the ramus of mandible is  $15.92 \pm 2.52$  mm on right side and  $16.12 \pm 2.24$  mm on left side, from posterior border of the ramus of the mandible is  $12.64 \pm 2.10$  mm on right side and  $12.83 \pm 2.04$  mm on left side, from mandibular notch is  $21.23$  mm on right side and  $21.16$  mm on left side, from angle of mandible is  $21.78 \pm 3.20$  mm on right side and  $21.26 \pm 3.34$  mm on left side and from base of the mandible is  $24.80 \pm 3.00$  mm on right side and  $24.60 \pm 3.10$  mm on left side. AMFs were observed in 12% cases on right side and 16% cases on left side. **Conclusion:** Exact knowledge of MF is important for planning and conducting dental surgeries and knowledge of AMFs help the radiotherapists for planning of cancer treatment.

Copyright © 2018, Dr. Amita Sarkar. This is an open access article distributed under the Creative Commons Attribution License, which permits unrestricted use, distribution, and reproduction in any medium, provided the original work is properly cited.

Citation: Dr. Amita Sarkar. 2018. "A morphometric study of mandibular foramen and accessory mandibular foramina in adult human mandibles and its clinical implications", *International Journal of Development Research*, 8, (10), 23575-23578.

### INTRODUCTION

The medial or internal surface of the ramus of the mandible presents an irregular foramen-the mandibular foramen, a little above its centre leading into the mandibular canal curving downwards and forwards into the body of the mandible upto its mental foramen. The inferior alveolar vessels and nerve pass through this foramen and traverse the mandibular canal to supply the teeth of lower jaw (Standring, 2008). Any openings in the mandible other than the sockets of teeth, mandibular foramina, mental foramina and lingual foramen are referred as accessory mandibular foramina (AMF) (Sutton, 1974). One of the commonest anaesthetic procedure in dental practice is inferior alveolar nerve block. Failure rate of this technique is also high due to inaccurate localization of mandibular foramen due to variability in its position (Ennes and Medeiros, 2009; Oguz, 2002). The absence of a specific anatomic bony landmark, along with variations in the ramus width and height and the inferior alveolar nerve foramen position, is responsible for failure to achieve proper anaesthesia.

\*Corresponding author: Dr. Amita Sarkar

K. P. C. Medical College & Hospital Under West Bengal University of Health Sciences

Some authors have estimated the failure rate of inferior alveolar nerve block to be approximately 20-25% (Funibundak and Matthews, 1999). Presence of AMFs and additional branches of inferior alveolar nerve passing through them may also be a cause of failure of nerve block. However, AMFs may sometimes only be associated with blood vessels without any nerve element. For that reason AMFs are not always associated with difficulty in mandibular anaesthesia (Lew, 2006). Another importance of AMF is that it acts as a route for spread of infection and tumour cells. A number of nerves like facial, mylohyoid, buccal, transverse cutaneous nerve may pass through the accessory mandibular foramen (AMF) and if local anaesthesia is given in such cases the failure rates are high as the inferior alveolar nerve branches are not completely anaesthetized (Hayward *et al.* 1977). The accessory mandibular foramen can be the site for the spread of tumours following radiotherapy. The knowledge of the additional foramina may be important for the radiotherapists while planning radiation therapy (Funibundak and Matthews, 1999). Considering the clinical importance of mandibular foramen, the present study was done to determine the precise location of the mandibular foramen in relation to different bony landmarks

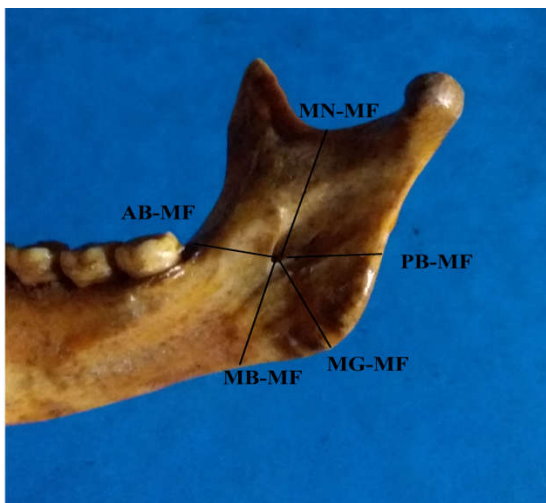
of the mandibular ramus and to determine the incidence of occurrence of accessory mandibular foramen.

### Aims and Objectives

The aim of the present study was to identify the exact location of mandibular foramen in relation to different bony landmarks of the ramus of mandible and the incidence of accessory mandibular foramina which will help the dentists and clinicians in modifying the technique of inferior alveolar nerve block to overcome the failure.

### MATERIALS AND METHODS

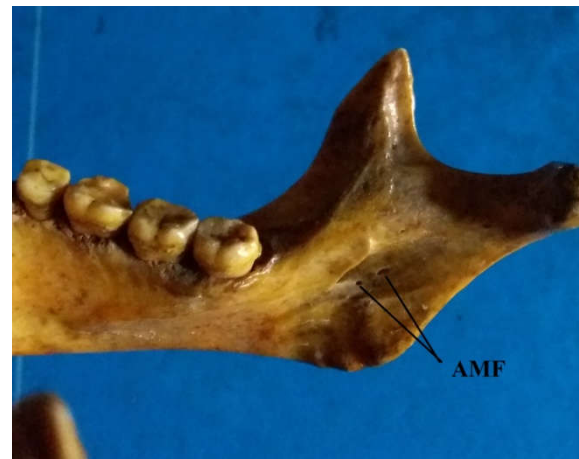The present study was carried out in 50 adult human mandibles of unknown age and sex collected from different medical colleges of Kolkata. Diseased and damaged mandibles were excluded from the study. The position of the mandibular foramen from various landmarks were recorded on both the sides of the mandibular ramus. The measurements were taken with the help of the Vernier caliper calibrated to measure upto 0.1mm. The position of the center of mandibular foramen was measured from various landmarks like, 1. Anterior border of the ramus of mandible (AB-MF), 2. Posterior border of the ramus of the mandible (PB-MF), 3. Mandibular notch (MN-MF), 4. Angle of the mandible i.e. meeting point of base with posterior border of ramus (MG-MF) and 5. Base of the mandible (MB-MF). The distances from the mandibular foramen to various bony landmarks were recorded as an average of three independent measurements. The mean and standard deviation were calculated separately for right and left sides and tabulated. The mandibles were examined further for the presence of single and multiple accessory mandibular foramen with the help of a magnifying lens and the incidence of its occurrence was noted (Fig. 1 and Fig. 2).



**Figure 1.** Showing measurements of mandibular foramen from various landmarks of mandible – anterior border (AB-MF), posterior border (PB-MF), mandibular notch (MN-MF), angle of mandible (MG-MF), base of the mandible (MB-MF)

### RESULTS

A total of 50 adult dry human mandibles were studied for the position of mandibular foramen. The minimum, maximum, average and standard deviation values of the various parameters which were studied on either side of the mandible are shown in Table 1.



**Figure 2.** Showing accessory mandibular foramina on medial surface of mandibular ramus

The mean distance of mandibular foramen from, 1. Anterior border of the ramus of mandible is  $15.92 \pm 2.52$  mm on right side and  $16.12 \pm 2.24$  mm on left side 2. Posterior border of the ramus of the mandible is  $12.64 \pm 2.10$  mm on right side and  $12.83 \pm 2.04$  mm on left side 3. Mandibular notch is 21.23mm on right side and 21.16 mm on left side 4. Angle of mandible is  $21.78 \pm 3.20$  mm on right side and  $21.26 \pm 3.34$  mm on left side. 5. Base of the mandible is  $24.80 \pm 3.00$  mm on right side and  $24.60 \pm 3.10$  mm on left side. Accessory mandibular foramina was observed in the 6 mandible on right side (12%) and eight mandible on left side (16%) Table 2.

**Table 1.** Distance of Mandibular Foramen from various landmarks of mandible

Measurement	Side	Mean $\pm$ SD (mm)
AB-MF	Right	$15.92 \pm 2.52$
	Left	$16.12 \pm 2.24$
PB-MF	Right	$12.64 \pm 2.10$
	Left	$12.83 \pm 2.04$
MN-MF	Right	$22.60 \pm 3.00$
	Left	$22.34 \pm 2.94$
AG-MF	Right	$21.78 \pm 3.20$
	Left	$21.26 \pm 3.34$
MB-MF	Right	$24.80 \pm 3.00$
	Left	$24.60 \pm 3.10$

MF - Mandibular foramen, AB - Anterior border, PB - Posterior border, MN - Mandibular notch, AG - Angle of the mandible, MB - Base of the mandible

**Table 2.** Incidence of Accessory Mandibular foramina

AMF	Number	Percentage
Right side	6	12%
Left side	8	16%

AMF – Accessory Mandibular Foramen

### DISCUSSION

Mandibular foramen is an important landmark for mandibular orthognathic surgeries. The location of mandibular foramen is clinically crucial in achieving inferior alveolar block. The position of mandibular foramen has been found to be variable which made it difficult to anaesthetize inferior alveolar nerve (Nicholson, 1985). Inferior alveolar nerve is also at a higher risk to be injured during mandibular surgeries like sagittal split osteotomy. Various parameters have been used by different researchers to locate the mandibular foramen. There are significant differences reported in the location of MF among different ethnic groups. Mbajorgu EF (Mbajorgu, 2000)

studied 38 dry mandibles of adult black Zimbabweans and recorded that the mandibular foramen on an average lies at about 2.56 mm (right) and 2.08 mm (left) behind the midpoint of ramus width and at approximately 3 mm superior to the midpoint of ramus height on both sides. Oguz O (Oguz, 2002), studied 34 dried young Turkish adult human male mandibles and noted the distance of the mandibular foramen to the anterior border of ramus was 16.9 mm on the right and 16.78 mm on the left side. The distance to the posterior side of the ramus was 14.09 mm on the right, and 14.37 mm on the left side. The distance of the lowest point of mandibular notch to the foramen was 22.37 mm on the right and 22.17 mm on the left. The distance from the mandibular foramen to the inferior border of the ramus in the mid position of the ramus was 30.97 mm on the right and 29.75 mm on the left side. The present study is comparable to the study of Oguz.O. Sang Wan Lee (Sang Wan Lee, 2012) studied 104 dried mandibles (65 males, 39 females) from Korean cadavers and found that, the mandibular foramen was located posteriorly to the midpoint on the Antero-posterior (AP) width of the ramus. It was located at 57.3% of AP width from the coronoid notch and 56.5% from the occlusal plane. The mandibular foramen and the tip of lingula were located superiorly to the midpoint on the vertical height of the ramus, on the 48.5% and 35.7% of vertical distance from the coronoid notch respectively. Hayward et al (Hayward, 1977), studied 107 dried mandibles and demonstrated that the Antero-posterior location of the MF was at the third quadrant of mandibular ramus and differences between the right and left ramus were non-significant. Another study from Pakistan by Asma Saher Ansari *et al* (Ansari Asma Saher, 2015) on 152 panoramic radiograph of mandibles, it was found that mean distance from mandibular foramen to anterior border was  $17.69 \pm 0.61$  mm on right side,  $17.65 \pm 0.63$  mm on left side in females and was  $17.55 \pm 0.68$  mm on right side,  $17.56 \pm 0.81$  mm on left side in males. From posterior border it was  $12.03 \pm 1.02$  mm on right side,  $11.84 \pm 0.70$  mm on left side in females and was  $12.66 \pm 1.23$  mm on right side,  $12.52 \pm 1.84$  mm on left side in males. From mandibular notch the distance was  $20.51 \pm 0.92$  mm on right side,  $21.03 \pm 0.90$  mm on left side in females and was  $20.45 \pm 1.02$  mm on right side,  $21.28 \pm 0.85$  mm on left side in males. (Samanta Pragna Paramita, 2013) studied 60 mandibles from North part of India. According to them mandibular foramen was located  $15.75 \pm 2.92$  mm (R) and  $16.23 \pm 2.88$  mm (L) distant from the anterior border,  $13.29 \pm 1.74$  mm (R) and  $12.73 \pm 2.04$  mm (L) from the posterior border. It was positioned  $22.7 \pm 3.0$  mm (R) and  $22.27 \pm 2.62$  mm (L) away from the mandibular notch. The distance of mandibular foramen from the angle of mandible was  $21.54 \pm 2.92$  mm (R) and  $21.13 \pm 3.43$  mm (L).

The values recorded in the present study, maintains bilateral symmetry which is similar to other studies. The passage of blood vessels and nerves makes the AMF clinically important. The embryological basis of the occurrence of the AMF has been described in the literature (Chavez Lomeli, 1996). During the initial period of development, three inferior alveolar nerves were present, which innervate each of the three groups of the mandibular teeth. These three nerves fuse later and a single inferior alveolar nerve is formed. The incomplete fusion of these three nerves leads to the development of double mandibular canals. It was reported that, in 60% of the cases, the mandibular canal was found to have the entire inferior alveolar nerve passing through it, while, in the remaining 40% cases, the nerves were found to be scattered. Reported cases of

accessory mandibular foramina are very low. In a Brazilian population 27.93% and 43.24% of the mandibles presented accessory mandibular foramina located either below or above the mandibular foramen respectively (Freire, 2012). According to (Pragna Paramita, 2013), AMF was found in 16.66% of the mandibles. In the present study accessory mandibular foramina were present in 12% cases on right side and 16% cases on the left side.

## Conclusion

The morphological knowledge of the MF is of paramount importance in achieving inferior alveolar nerve block during the dental procedures of the lower jaw like osteotomy, orthognathic reconstruction surgeries of the mandible and dental implant procedures and to avoid injury to the neurovascular contents passing through it. The AMF are known to transmit the branches of the inferior alveolar nerve and extra blood vessels which supply the bone. The position of the MF is variable, making it difficult to anaesthetize the inferior alveolar nerve successfully. Accessory mandibular foramina will serve as a route for spread of infection and tumor cells. The present study concludes that the exact knowledge of the position of mandibular foramen is important for planning and conducting dental surgeries for its effective management and knowledge of accessory mandibular foramina will help the radiotherapists to plan the treatment of cancer.

## REFERENCES

- Ansari Asma Saher and Ahmed Imtiaz, 2015. Localization of the mandibular foramen on the panoramic radiographs 27(3):576-579.
- Chavez Lomeli, M.E., Mansillalory, J., Pompa, J.A., Kjaer, I. 1996. The human mandibular canal arises from three separate canals, innervating different tooth groups. *J Dent Res*, 75, 1540-4.
- Das, S. and Suri, R.K. 2004. An anatomico-radiological study of an accessory mandibular foramen on the medial mandibular surface, *Folia Morphol*, 63, 511-13.
- Ennes, J.P., Medeiros, R.M. 2009. Localization of mandibular foramen and clinical implication. *Int J Morphol.*, 4:1305–1311.
- Freire, A.R., Rossi, A.C., Prado, F.B. 2012. Incidence of the mandibular accessory foramina in Brazilian population. *J Morphol Sci.*, 29:171-173.
- Funibundak and Matthews, J.N.S. 1999. Relationship between accessory foramina and tumour spread in the lateral mandibular surface, *J Anat.*, 195, 185-90.
- Hayward, J., Richardson, E.R., Malhotra, S.K. 1977. The mandibular foramen: Its anteroposterior position, *Oral Surg Oral Med Oral Pathol*, 44, 837-843.
- Lew, K., Townsen, G. 2006. The failure to obtain adequate anaesthesia is associated with a bifid mandibular canal: a case report. *Aust Dent J.*, 51: 86-90.
- Mbajiorgu, E.F. 2000. A study of the position of the mandibular foramen in adult black Zimbabwean mandibles, *Cent Afr J Med*, 46(7), 184-90.
- Nicholson, M.L. 1985. A study of the position the mandibular foramen in the adult human mandible. *Anat Rec* 212 : 110-112.
- Oguz, O.I., Bozkir, M.G. 2002. Evaluation of location of mandibular and mental foramina in dry, young, adult human male, dentulous mandibles, *West Indian Med J*, 51(1), 14-6.

- Samanta Pragna Paramita, Kharb Poonam. 2013. Morphometric analysis of mandibular foramen and incidence of accessory mandibular foramina in adult human mandibles of an Indian population. *Rev Arg de AnatClin.*, 5(2):60-66.
- Sang Wan Lee, *et al*, 2012. A Morphometric Study on the Mandibular Foramen and the Lingula in Korean, *Korean J PhysAnthropol*, 25(4), 153-166.
- Standring S. 2008. Gray's Anatomy, The anatomical basis of clinical practice, 40th edition. Churchill livingstone, Elsevier. Chapter-31, Page 530- 533, 595-614.
- Sutton RN. 1974. The practical significance of mandibular accessory foramina. *Aust Dent J.*, 19:167-173.

\*\*\*\*\*