

ORIGINAL RESEARCH ARTICLE

OPEN ACCESS

## PREPARATION, ASSEMBLY AND OSTEOLOGICAL DESCRIPTION OF A BROCKET DEER SPECIMEN (FISCHER, 1814)

<sup>1</sup>Cristiane Elise Teichmann, <sup>1</sup>Gabriele Maria Callegaro Serafini, <sup>2</sup>Andressa Machado Palharini, <sup>3</sup>Orestes Moraes Cabeleira, <sup>3,\*</sup>Bruna Carolina Ulsenheimer and <sup>3</sup>Guilherme Hammarström Dobler

<sup>1</sup>Professor Veterinary Medicine Course of the Northwestern University of the state of Rio Grande do Sul, Brazil

<sup>2</sup>Undergraduate degree in Biology by the Northwestern University of the state of Rio Grande do Sul, Brazil

<sup>3</sup>Under graduate of Veterinary Medicine Course of the Northwestern University of the state of Rio Grande do Sul, Brazil

### ARTICLE INFO

#### Article History:

Received 21<sup>st</sup> October, 2018

Received in revised form

03<sup>rd</sup> November, 2018

Accepted 19<sup>th</sup> December, 2018

Published online 30<sup>th</sup> January, 2019

#### Key Words:

*Mazama gouazoubira*, didactic material, skeleton, osteoethnics, osteometry

### ABSTRACT

The description of the technique of preparation and assembling of a skeleton of brocket deer *Mazama gouazoubira* (Fischer, 1814), received without life by the Laboratory of Zoology and Ichthyology Regional University of Northwestern region of the state of Rio Grande do Sul (UNIJUI), Ijuí -RS were the aims of this study. The preparation of the skeleton followed the steps: complete strip of the animal by means of manual maceration with cooking, the bones clarification, mounting and jointing of the bones ending with the fixing of the skeleton on a wooden base. The choice of maceration method and its cooking were essential to obtain a skeleton of quality. To mount the specimen the anatomical knowledge of similar species and the knowledge of the behavior related to their habitat determined the position and location of each anatomical structure enabling to have a quality result and trustworthy regarding the animal when alive. The skeleton description was performed based on observation and measurement of the bones with the aid of a tape measure. The proposed work resulted in an excellent example of a fixed skeleton of brocket deer (*Mazama gouazoubira*) whose material will contribute as a tool of didactic nature for scientific research on approaches to environmental education.

Copyright © 2019, Cristiane Elise Teichmann et al. This is an open access article distributed under the Creative Commons Attribution License, which permits unrestricted use, distribution, and reproduction in any medium, provided the original work is properly cited.

Citation: Cristiane Elise Teichmann, Gabriele Maria Callegaro Serafini, Andressa Machado Palharini, 2019. "Preparation, assembly and osteological description of a brocket deer specimen (Fischer, 1814)", *International Journal of Development Research*, 9, (01), 25058-25061.

## INTRODUCTION

The brocket deer *Mazama gouazoubira* (FISCHER, 1814) is a small-sized species, with an average weight of 18 kg and average height of 50 cm at the withers. Its coloration can vary from dark gray to reddish brown. The ventral region of the abdomen is BAIA, with white areas on the underside of the tail and the inner face of the ear. The submandibular and periophthalmic regions are clearer. The majority of individuals have a white spot above the eyes, which is non-existent in other species of deer (VATS *et al.*, 2007). It belongs to one of eight species of ruminants of the family Cervidae living in Brazil. It may be present in forests, riparian forests, open cerrados and secondary forests. It is estimated that the populations are in balance or in growth due to the ability to occupy anthropized areas. With a total population of 10,000 adult individuals (DUARTE *et al.*, 2012).

\*Corresponding author: Bruna Carolina Ulsenheimer,

Under graduate of Veterinary Medicine Course of the Northwestern University of the state of Rio Grande do Sul, Brazil.

Generally, the neotropical cervids are still little studied. This shortage is generated by the difficulty of access to the animals (CUBAS *et al.*, 2007). However, it has been observed that there are increasingly more cases of treatment of these animals by veterinary surgeons. These visits, in general, are given in virtue of accidents such as running over and attacks by domestic dogs, caused by the proximity of these animals to urban centers (PARANÁ, 2006). The toppling of specimens in scientific collections and didactic allows a range of materials to be stored for studies of identification, classification, morphology and adaptation. Therefore, it is understood that collections are of great scientific and social importance, as well as they represent the existing biodiversity (SILVEIRA; OLIVEIRA, 2008). According to Rodrigues (2010) skeletons are important tools for both scientific research in the identification of anatomical characters for phylogenetic analyzes and, as for didactic purposes, illustrating the body structure, as well as for greater knowledge of the anatomical structures of this kind, in case there are any clinical or surgical service provision (RODRIGUES, 2010). There are several

techniques for the extraction of the vertebrates skeleton, such as the use of chemical, biological or mechanical processes (Silveira *et al.*, 2008), applied alone or in combination. Given the above and the need for more information about the deer's anatomical characteristics, the objective of this study is to describe the preparation, assembly and osteological description of a specimen of brocket deer.

## MATERIALS AND METHODS

A male brocket deer, *Mazamagouazoubira*, with less than one year of age was brought to the campus of the Western University of the state of Rio Grande do Sul, by the Environmental Surveillance of Ijuí, no longer alive due to a runover, being donated to anatomy studies and taxidermy techniques to the Laboratory of Zoology and Ichthyology of UNIJUI. After the arrival of the animal, the same was frozen in conventional freezer maintained at a temperature of  $-18^{\circ}\text{C}$  and remained for six months, until the moment of the procedure. After defrosting, skin was removed through a ventral cut across the length of the body starting in the region of the mandible and following up to the pelvic region, taking care not to penetrate the body cavities and injure some viscera. All the skin was removed for subsequent procedures. A wire was put in the entire length of the vertebral column to assist in securing the region. The thoracic and abdominal cavities were open for the viscera removal. Following it was started the strip phase by removing the excess of muscles with surgical instruments of dissection, such as tweezers, scalpels and scissors, always taking care not to injure any bone. With the completion of this procedure the bones still with muscular and articular segments remnants were grouped by anatomical regions in sachets made with 100% viscose fabric and bacteriostatic agent<sup>1</sup> and placed in a pot for cooking with chopped green papaya during four hours. At the end of cooking, one more cleaning stage was performed, in which all muscular and articular remnants were removed using the same surgical instruments. For a better result, the bones were placed into a bucket with 20 liters of water and 250 ml of detergent, where they remained for three weeks. The water was renewed every two days to avoid the darkening of the parts, bacterial proliferation, larvae and insects, as well as the impregnation of the putrid odor of the deterioration of remaining tissues. With the bones clean, lightening process was begun using oxygenated water at 30 volumes. The immersion time of the bones in oxygenated water ranged from two days to the smaller bones and seven days for the larger ones. After that time, they were left to dry in the shade. The bones were set (glued) with glue made by mixing of epoxy resin and hardener polyamine<sup>2</sup>.

The regions of larger joints were fixed with wire. The skeleton ready was fixed in a wooden base to support and preservation of material. The bones and bone injuries measurement was performed with the aid of a tape measure, where the results were recorded for further discussion. To assemble the specimen mastery of the animal's anatomy was essential and the knowledge on the behavior associated with its habitat, which determined the position and location of each anatomical structure and the articulation of its limbs, thus enabling to have a quality result and trustworthy character in relation to the animal when alive (Figure 1).

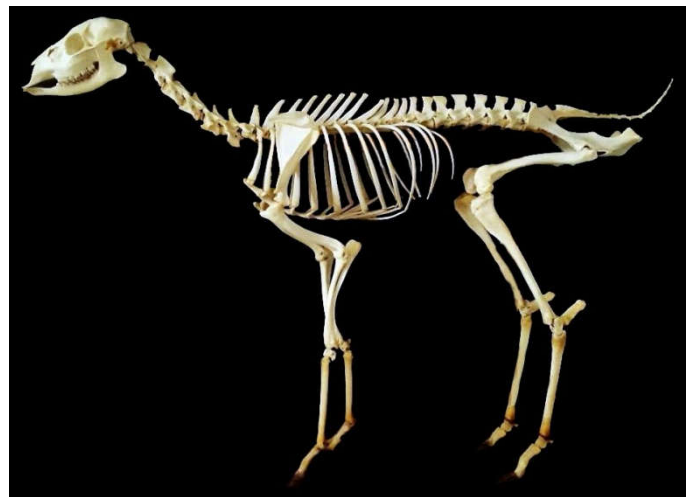


Figure 1. Brocket deer skeleton (FISCHER, 1814)

## RESULTS

The evaluated brocket deer skeleton *Mazama gouazoubira* presented the following description

**Vertebral Column:** The vertebral formula found was C7, T13, L6, S5, Ca9. The cervical vertebrae were short and wide, being that at the atlas, the dorsal tuberculum was little developed and the wings were designed in a caudolateral position. The spinous process of the axis joint was narrow caudally and the other following vertebrae were less developed and increased length of the third until the last vertebra. The transverse processes were divided into two branches, which increased in size from the third to fifth vertebra. The sixth cervical vertebra presented the transverse process with quadrilateral format directed ventrally. The seventh transverse process was unique, short and thick. The thoracic vertebrae showed relatively large bodies, forming intervertebral foramina. The lumbar vertebrae had planed dorsoventrally bodies, being the articular processes strongly curved and superimposed to the caudal ones. The transverse processes bent cranially, increasing the size from the first to the third vertebra and keeping the same size in the fourth and then decreases in the fifth and the sixth ones. In the sacrum there was no vascular groove at the pelvic face. The sacral spine of the first vertebra was separate from the others, and in the following ones joined forming the median sacral crest. The caudal vertebrae had long transverse processes in the first vertebrae and thin, designed caudally at the others. The first two ones had bow and spinous process that kept decreasing in size until fading away in the fourth vertebra and the other kept only the body until the last one.

**Ribs:** it presented 13 pairs of ribs of which eight were true (sternal) and five false (asternal) forming the costal arch, the external surface was smooth and rounded. Sternum: formed by seven segments. The first is cylindrical with extended ends, the others are broad and plain looking flattened toward ventral dorsum, the xiphoid cartilage is large.

**Thoracic limbs:** The scapula presented dorsal large edge and narrow neck, spine prominent, without tuberosity and with developed acromion and supraspinatus fossa is extremely short. Measurements made had 12 cm of longitudinal length, 6.5 cm from the vertical flow angle at the end of the supraspinous fossa and 2.5 cm vertical on the lap. The humerus was relatively long and slender, the cranial portion

<sup>1</sup>PerfexYPÊ –Industria Brasileira Salto-SP

<sup>2</sup>Poxipol transparent -TBR Adesivos e Selantes Ltda. - Curitiba - Paraná.

was not bent and did not present deltoid tuberosity. The humerus presented 14 cm of longitudinal measurement. The radius was long, slightly bent and its dorsal face was rounded. The body of the ulna was thinner, especially in its distal half, measurement of the radius was 14 cm and the ulna of 16.5 cm longitudinal length. Forming the region of the hand six carpal bones were found arranged in two rows, being formed by four bones proximal and distal by two bones. The great metacarpal was long and slender with no dorsal sulcus. The phalanges of the main fingers were long and narrow, the distal phalanx was overlapped by the hull.

**Pelvic limbs:** at the coxal bone the axis of the ilium was almost in a line with the Ischium, the gluteal line appeared as a crest which was proximally parallel with the lateral edge. The ischial tuberosity presented a pointed lateral process and a dorsal short prominence. The ventral tubercle was low in the pelvic symphysis. The opening of the pelvis showed elliptical contour, the conjugate diameter was 8.5 cm and the transverse diameter had 5 cm. The obturator foramen had an elliptical and narrow shape. The femur presented a slightly bent body, head and neck were distinct, the greater trochanter was higher than the head, the trochlea crests were similar and parallel. The measurements were 18 cm in length and 5 cm in width. The tibia was long and slender, the fibula had no body and its proximal epiphysis was represented by a distal prominence to the lateral margin of the tibia lateral condyle. The foot was formed by the tarsus, consisting of talus, calcaneus with developed calcaneal process, the tarsus center was merged and IV tarsals merged, III and II tarsals merged. The metatarsal bones of the fingers were long, measuring 17 cm in length and had the same characteristics corresponding to the thoracic limbs, with the exception of presenting a deep dorsal sulcus. Head: there were flat and serrata sutures among the bones of the skull. The identified bones were occipital, parietal, frontal, sphenoid, mandible, maxillary sinus, nasal, frontal, temporal, zygomatic bones, lacrimal and incisive. It had teeth of the kind molars and pre-molars, incisors at number eight and absence of canines. It had a total of 32 teeth, with 16 of each hermiarcade.

## DISCUSSION

The knowledge of the morpho functional characteristics of wildlife provides grounding for clinical, surgical and diagnostic imaging procedures for veterinarians in units of conservation and zoos, as well as assists with information for conservation strategies. The production of differentiated bone pieces as didactic material encourages learning through the study of anatomy and the team work, in addition to providing complete skeletons and high quality parts for laboratories (JIMENEZ *et al.*, 2015). The skeleton is composed of some elements, such as bones, cartilage, ligaments and joints, which, in its entirety, form the first of a system of body frame, the skeletal system (LIEBICH, 2011). With the confection of this skeleton it is intended to supply the need of osteological material available in the collection of the Laboratory of Zoology and Ichthyology to assist Professors and students in the practical classes courses in biology and Veterinary Medicine of UNIJUI. Upon the practical development of this work it was possible to evaluate the complexity of the process of preparation and assembly of this type of osteological material. Many factors influence directly and indirectly to achieving a satisfactory result and, to this end, it is essential according to Silveira *et al.* (2008) that the destination of the material to be prepared be determined before the start of any

procedure. However, the state of conservation of the same at the time of collection and preparation may also influence at its destination. In this case, in particular, the whole corpse, stored properly and in a good state of conservation, allowed that it would be intended for mounting of the skeleton. The osteotechnics are geared to the preparation and improvement of anatomical pieces for the practical anatomy teaching of the musculoskeletal system. It is justified the development of this technique by the need to occur dynamization of the preparation and improvement process of anatomical pieces for teaching the musculoskeletal system, so that there is a communication between practice and theory. There are several techniques (osteotechnics) for the extraction of the vertebrates skeleton, such as the use of processes with hydrogen peroxide (KAWAMOTO *et al.*, 2010), biological or mechanical with tweezers and scalpels (SILVEIRA *et al.*, 2008), applied alone or in combination. For the preparation of this specimen three techniques were used in accordance as described by Rodrigues (2010), the technique of maceration by digestion of the tissues using papain, chemical maceration using soap and water, and the technique of bleaching using hydrogen peroxide 30 volumes, techniques that have been proven effective in preparing the brocket deer skeleton. To Silveira *et al.* (2008) the chemical processes are generally the most aggressive, but allow to get faster results. The use of oxygenated water in chemical maceration shows a satisfactory outcome when the parts go through a boiling process. Silveira *et al.* (2008) still consider water an excellent method to maceration of bone pieces, but which contains as inconvenience the delay and the bad smell due to the tissues decomposition. In fact, the delay was observed in this study, since three weeks were necessary to reach the expected result. About the smell, the same was avoided with the exchanges of water every two days and the addition of detergent in the solution. Thus, taking into account the practicality, low cost and result obtained with this method, the authors of this study corroborate with the opinion of Silveira and Oliveira (2008). Osteometry characterized in detail the skeleton bones proportion of this specimen for which functional correlations could be made, it may be noted that the skeleton of *M. gouazoubira* is similar to that of domestic ruminants described by Sisson (1981), calling attention to the way proportionally more lengthened of all long bones of the limbs probably characterizing an adaptation of this species, which provides a faster locomotion. According to Bombonato *et al.* (2005) the difference in speed of the animals' walking is dependent on the bones length located in the limbs of each animal. According to Zaher and Young (2003) the majority of the zoological collections were made due to isolated efforts of institutions and researchers. This work has not occurred in a different way, because despite the knowledge on cleaning and preparation techniques being essential for completion of this work, the entire assembly process was performed in a pioneer way in this lab which required research, dedication, creativity, skill and patience of professionals and students involved in this process.

## Conclusion

The finalization of this osteological preparation process resulted in important confection of one more, among few articulated skeletons of this type of mammal. The excellent final result, confirmed that the techniques used in this study were effective and well employed for this set of situations. Through the obtained studies and results it was possible to prove that the brocket deer's structures and bone injuries are

similar to those described for other domestic ruminants. This specimen of a brocket deer's fixed skeleton (*Mazama gouazoubira*), will contribute as a tool of didactic nature for scientific research on approaches to environmental education, as well as to have greater knowledge about their anatomical structure in cases of clinical or surgical cases involving this species.

## REFERENCES

- BOMBONATO, P., MORAES, V., OLIVEIRA, G. 2005. Biomecânica canina. In: Mikail S., CR P, editors. *Fisioterapia Veterinária*. São Paulo; p. 13–7.
- CUBAS, Z.S., SILVA, J.C.R., CATÃO-DIAS, J.L. 2007. *Tratado dos Animais Selvagens*. 2nd ed. Editora Roca, editor. São Paulo, p. 641.
- DUARTE, J.M.B., PIOVEZAN, U., ZANETTI, E. DO S., RAMOS, H.G. DA C. Plano de Ação Nacional para a Conservação dos Cervídeos Ameaçados de Extinção. In: *Espécies de Cervídeos Brasileiros Não Ameaçadas de Extinção*. Instituto Chico Mendes de Conservação da Biodiversidade, p. 20–7, 2012.
- JIMENEZ, K.N., BARRETO, L.V., SANTOS, D., FAVARO, J.R. 2015. Aplicação da osteotécnica no ensino da anatomia pela preparação e montagem do esqueleto de um *Ramphastossulphuratus*. *Concepar*.
- KAWAMOTO, S.H., PACHECO, M.L., ALVES, F., MARTINS, G.R. 2006. Confecção da coleção osteológica de referência (Mastofauna e Ictiofauna) para aplicação em estudos zoológicos em Mato Grosso do Sul. *An da 58ª Reunião Anu da SBPC* [Internet]. p. 1–2., Availablefrom: <<http://www.sbpcnet.org.br/livro/58ra>>
- LIEBICH, H.G., LIEBICH, H.G. 2011. *Anatomia dos Animais Domésticos*. 4th ed. São Paulo: Artmed; p. 788.
- PARANÁ, I.A. DO. 2006. *Planos de Conservação para Espécies de Mamíferos Ameaçados*. Londrina.
- RODRIGUES, H. 2010. Osteotécnicas. In: Editora GG e, editor. *Técnicas Anatômicas*. Vitória-ES: H. Rodrigues; p. 15–43.
- SILVEIRA, M.J. DA., TEIXEIRA, G.M., OLIVEIRA, E.F. DE. 2008. Análise de processos alternativos na preparação de esqueletos para uso didático. *Acta Sci - BiolSci.*, v. 30, n. 4, p. 465–72.
- SILVEIRA, M.J. DA; OLIVEIRA, E.F. DE. 2008. A importância das coleções osteológicas para o estudo da biodiversidade. *Rev Saúde e Biol*, v. 3, n. 1, p. 1–4.
- SISSON, S. 1981. Osteologia dos Ruminantes. In: Getty R, editor. *Anatomia dos animais domésticos*. Rio de Janeiro: Artmed; p. 693–735.
- ZAHER, H., YOUNG, P.S. 2003. As coleções zoológicas brasileiras: panorama e desafios. *Cienc Cult.*, v. 55, n. 3, p. 24–6.

\*\*\*\*\*