



RESEARCH ARTICLE

OPEN ACCESS

## ABDOMINO INGUINAL APPROACH FOR RETROPERITONEAL SARCOMA

\*<sup>1</sup>Balamurugan, S.G., <sup>2</sup>Kalpana, B., <sup>3</sup>Lesin Kumar, A. N. and <sup>3</sup>Giles Fanny, A.

<sup>1</sup>Surgical Oncologist, Guru Hospital, 4/120F, Ring road, Uthangudi, Madurai, Tamilnadu

<sup>2</sup>FNB reproductive Medicine, Obstetrician and Gynecologist, Guru Hospital, 4/120F, Ring road, Uthangudi, Madurai, Tamilnadu

<sup>3</sup>DNB General Surgery, Consultant surgeon, Guru Hospital, 4/120F, Ring road, Uthangudi, Madurai, Tamilnadu

### ARTICLE INFO

#### Article History:

Received 12<sup>th</sup> May, 2019  
Received in revised form  
16<sup>th</sup> June, 2019  
Accepted 26<sup>th</sup> July, 2019  
Published online 28<sup>th</sup> August, 2019

#### Key Words:

Retroperitoneal sarcoma,  
Abdominoinguinal incision.

### ABSTRACT

The abdominoinguinal incision allows a vast improvement in the exposure and resectability of tumors in the lower abdomen with fixation to the pelvic side wall. A midline abdominal incision is connected to a longitudinal inguinal incision across the inguinal ligament. The pelvic side wall is directly exposed by detachment of the rectus muscle from its origin on the pubic crest and by division of the inguinal canal along the spermatic cord. This exposure allows safe resections along the iliac vessels without tumor spillage. The abdominoinguinal incision should be part of the armamentarium of every surgeon willing to accept responsibility for pelvic and pelvic side wall malignancy. 26 year old female who came with pedal edema and pain abdomen was diagnosed as retroperitoneal sarcoma. We have successfully excised the tumor by abdomino inguinal approach.

Copyright © 2019, Balamurugan et al. This is an open access article distributed under the Creative Commons Attribution License, which permits unrestricted use, distribution, and reproduction in any medium, provided the original work is properly cited.

Citation: Balamurugan, S.G., Kalpana, B., Lesin Kumar, A. N. and Giles Fanny, A. 2019. "Abdomino inguinal approach for retroperitoneal sarcoma", International Journal of Development Research, 09, (08), 29083-29085.

## INTRODUCTION

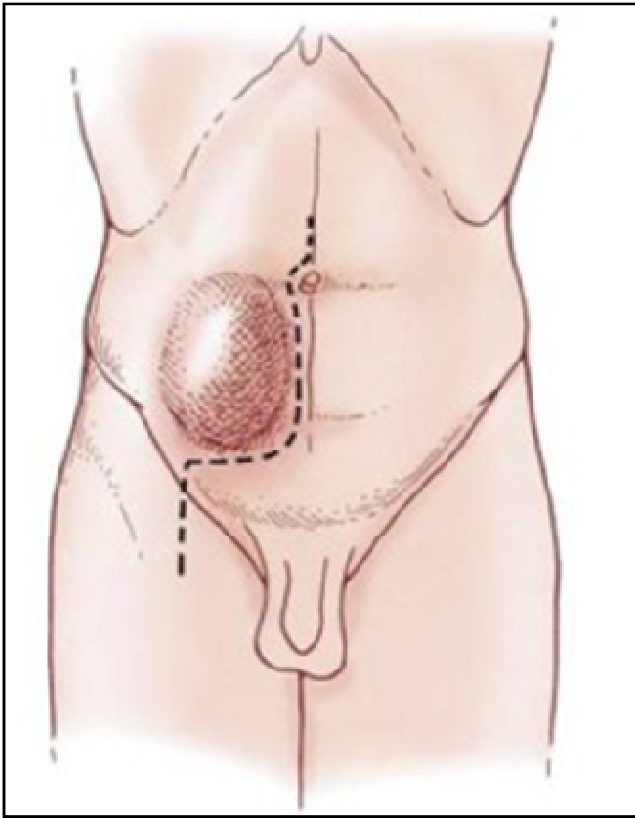
Retro peritoneal tumours, fortunately rare, are known to grow enormously before being diagnosed. Those arising from pelvis or present in true pelvis poses challenge in resection as the growth usually close to vital structures in those regions. Dissection of such tumours and giving a clearance margin for such tumours are rather possible without adequate exposure. The abdominoinguinal incision provides exposure and renders an unresectable large tumours located in the lower retroperitoneum, the area of external iliac vessels, and the wall of the pelvis resectable. It is particularly useful for tumors manifesting fixation to these areas. We are presenting one such rare case we encountered, who was having an unresectable tumour. we have also did a literature search and have discussed few salient points to be considered while managing such cases.

**Case Presentation:** Our patient is a 26 year old female with c/o swelling in the right lower limb for 3 months with vague abdominal pain and discomfort.

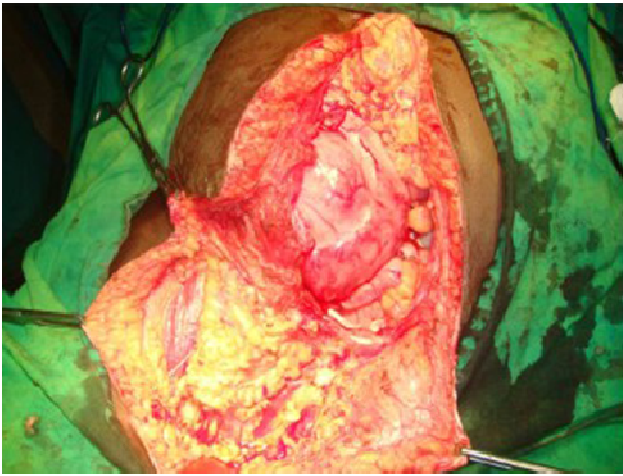
\*Corresponding author: Balamurugan, Surgical oncologist, Guru Hospital, 4/120F, Ring road, Uthangudi, Madurai, Tamilnadu

Examination showed Non tender hard fixed mass occupying RIF extending to right lumbar and hypogastric quadrants measuring 15 x 10 cm. patient had pitting pedal edema in the right lower limb with feebly felt DPA and PTA pulsations. She was evaluated with the following investigations. MRI abdomen & pelvis showed evidence of large mixed signal intensity lesion involving RIF originating from retroperitoneum attached to iliac muscle without bone destruction measuring 13.5 x 12.4 x 10.61 cms with extrinsic compression over iliac vessels without any e/o liver secondaries / LN enlargement MR Angio (aorto-iliac vessels) showed Lesion infiltrating the ilio psoas muscle engulfing the distal common iliac & entire course of external iliac arteries & veins.

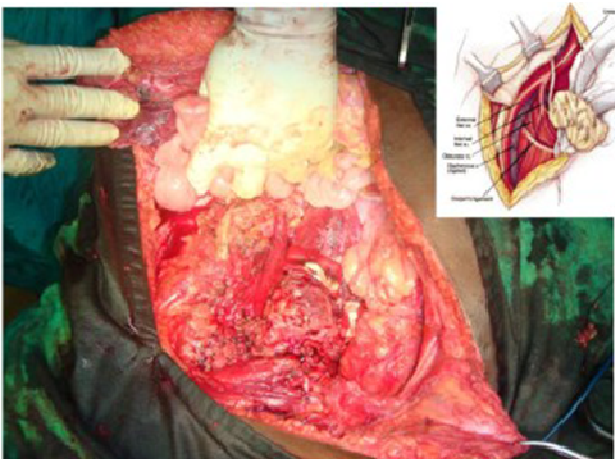
CT chest ruled out any lung secondaries / pleural effusion / mediastinal lymphadenopathy. Intra venous urogram revealed Large extrinsic impression noted on contrast filled bladder with mild dilatation of pelvi caecae system and upper 3<sup>rd</sup> ureter on the right side - s/o right HUN d/t compression. We took up this patient with retroperitoneal soft tissue sarcoma for wide local excision through abdomino inguinal approach.



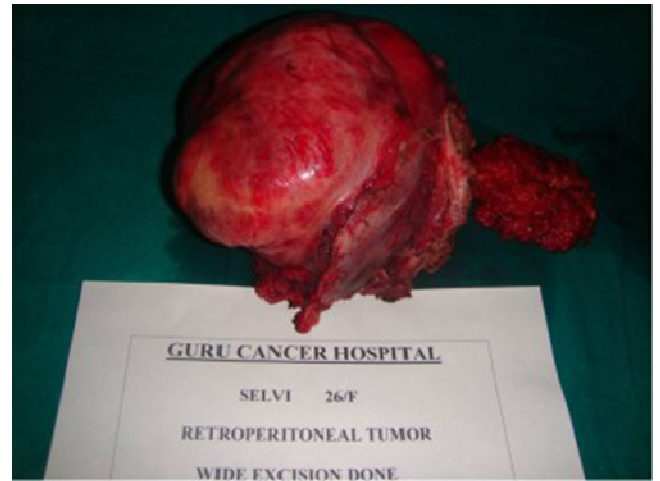**Fig. 1. Abdomino Inguinal Incision**



**Fig. 2. Tumour mobilization**



**Fig. 3. Tumour Bed**



**Fig. 4. Specimen**

## DISCUSSION

Pelvic tumors with lateral fixation present difficulties in their resection, primarily due to inadequate exposure through conventional abdominal incisions. The difficulty arises especially with tumors in the lower parts of the pelvis where the anterior abdominal wall converges with the retroperitoneal structures (e.g. iliopsoas muscle, iliac vessels). In this area the inguinal ligament spanning between the anterior superior iliac spine and the pubic tubercle provides an obstacle to unhindered exposure. Queral and Elias reported a two-stage procedure for removal of a sarcoma localized in the right iliac fossa with involvement of the iliac vessels.<sup>1</sup> In the first operation a femorofemoral bypass was performed from the left side to the right, and the common femoral artery was proximally ligated and divided. In the second operation, through an abdominal incision the mass was resected with en-bloc resection of a segment of the right iliac vessels, which were ligated and divided proximally. This example provides a solution to the distal control of the iliac vessels, but it requires two operations, and exposure at the time of resection of the tumor mass through an abdominal incision remains suboptimal. What is needed for the resection of these tumors is an incision that would simultaneously provide an in continuity in exposure of the abdominal cavity and one or both groins so that both iliac and femoral vessels would be exposed in one field. For this incision an abdominal component would be needed and an in continuity inguinal component, i.e. an abdominoinguinal incision. The inguinal ligament would have to be divided to allow uninterrupted exposure and control of the iliofemoral vessels. A lower midline incision provides good exposure of the intrapelvic structures. An inguinal incision exposes the femoral vessels. A transverse incision connecting the two, by dividing the origin of the rectus abdominis from the pubic crest and the insertion of the inguinal ligament to the pubic tubercle, provides the necessary link that allows a single incontinuity field and optimizes exposure. The abdominoinguinal incision may function much in the same way that the thoracoabdominal incision is used for the upper quadrants of the abdomen.

The indications for the abdominoinguinal incision are:

- Abdominal or pelvic tumors extending over the iliac vessels,
- Tumors in the iliac fossa

- Primary tumors, possibly involving the iliac vessels or large iliac lymph node metastases,
- Tumors with fixation to the wall of the true pelvis or large obturator nodes,
- Tumors involving the pubic bone with or without extension to the pelvis or adductor group of muscles, &
- Tumors of the groin when they involve the vessels of the lower abdominal wall or extend in the retroperitoneal area.

### Conclusion

The abdominoinguinal incision renders respectable the majority of pelvic tumors with lateral fixation to the soft tissues of the pelvis and, through improvement in exposure, allows for a safe, deliberate dissection. It is the counterpart of the thoracoabdominal incision for the upper quadrants of the abdomen. The results from the use of this incision obviously depend on the histologic type and stage of the tumor and the expected margin of resection one can thus obtain.

It should be used when appropriate and in the context of the biology of the tumor, the expected margin, and the possible use of adjuvant treatments.

### REFERENCES

- Karakousis CP. 1981. Ilioinguinal lymph node dissection. *Am J Surg.*, 141:299–303.
- Karakousis CP. 1982. Exposure and reconstruction in the lower portions of the retroperitoneum and abdominal wall. *Arch Surg.*, 117:840–4.
- Karakousis CP. 1984. The abdominoinguinal incision in limb salvage and resection of pelvic tumors. *Cancer.*, 54: 2543–8.
- Queral LA, Elias KG. Femorofemoral and venous bypasses in association with resection of a pelvic leiomyosarcoma. In General Surgery Motion Picture Session 10/24/84 of the American College of Surgeons, 1984 Clinical Congress.

\*\*\*\*\*