



ISSN: 2230-9926

Available online at <http://www.journalijdr.com>

IJDR

International Journal of Development Research

Vol. 13, Issue, 03, pp. 62181-62184, March, 2023

<https://doi.org/10.37118/ijdr.26500.03.2023>



RESEARCH ARTICLE

OPEN ACCESS

THE USE OF THE CICATRICAL ACCELERATION METHOD - M.A.C® - IN A MUSCLE INJURY ADDUCTOR GRADE 3: CASE REPORT

Marcus V.M. Pinto*¹, Nilton P. Vilardi Jr.², Vinicius T. Oliveira², Juliano Spinetti³, Aline R. Sampaio⁴, Esteban Fortuny⁵, Felipe Petrone², Caio H. O. Sauro², Roberto S. Tupinambá², Holf Flügel², Jorge Areãs² and Miriam V. Baron⁶

¹PhD and creator of the MAC® Method. Physiotherapist, CEO and Researcher of the Celulare Institute, Petrópolis, Rio de Janeiro, Brazil; ²Physiotherapist. Researcher and Fluminense Football Club. Rio de Janeiro RJ, Brazil; ³Fitness Coach and physiologist at Fluminense Football Club. Rio de Janeiro RJ, Brazil; ⁴Physiotherapist and researcher of the Celulare Institute. Petrópolis, Rio de Janeiro, Brazil; ⁵Physiotherapist and Researcher at Universidad Finis Terrae. CEO of Researcher and Diagnostra. Santiago, Chile; ⁶PhD, Physiotherapist, CEO of Instituto Interdisciplinar de Educação, Ciência e Saúde, Fortaleza, Ceará, Brazil

ARTICLE INFO

Article History:

Received 11th January, 2023

Received in revised form

03rd February, 2023

Accepted 14th February, 2023

Published online 30th March, 2023

KeyWords:

High-Performance; Laser; Muscle Injury; Photobiomodulation; Professional Soccer.

*Corresponding author: Marcus V.M. Pinto

ABSTRACT

This study presents a rare case of accelerated rehabilitation through the use of the Scar Acceleration Method (M.A.C®) in a high-performance athlete, a professional football player from the Brazilian Serie A Championship, after suffering a grade 3 muscular injury (according to the Munich consensus). This case report describes a patient who presented with grade 3 injury to the long adductor muscle, where M.A.C® was employed as a treatment method. Regular monitoring of the muscle's morphological evolution was conducted through ultrasonography. Muscular injuries pose a significant challenge for players and clubs, accounting for almost one-third of all time-loss injuries in male professional football. Given this information, it is pertinent to investigate strategies aimed at accelerating the muscular healing process, in order to reduce rehabilitation time and, consequently, minimize the impact of these injuries on the performance and career of athletes. The use of M.A.C® has proven to be an effective treatment in accelerating muscle healing/rehabilitation in high-performance athletes such as soccer players. It is important to share this methodology with the scientific community to encourage further studies and improve clinical practices in muscle injuries.

Copyright©2023, Marcus V.M. Pinto et al. This is an open access article distributed under the Creative Commons Attribution License, which permits unrestricted use, distribution, and reproduction in any medium, provided the original work is properly cited.

Citation: Marcus V.M. Pinto, Nilton P. Vilardi Jr., Vinicius T. Oliveira, Juliano Spinetti, Aline R. Sampaio, Esteban Fortuny, Felipe Petrone, Caio H. O. Sauro, Roberto S. Tupinambá, Holf Flügel, Jorge Areãs and Miriam V. Baron. 2023. "The use of the cicatricial acceleration method - m.a.c® - in a muscle injury adductor grade 3: case report". *International Journal of Development Research*, 13, (03), 62181-62184.

INTRODUCTION

Injuries to the adductor muscles are common among athletes who engage in high-intensity sports that require repetitive movements, kicking, and quick changes of direction, such as soccer. Adductor muscles are frequently involved, representing 23% of the injuries developed by soccer players per year. The adductor longus (AL) muscle originates from a narrow tendon of aponeurotic plate that crosses the pubic symphysis and inserts as a broad aponeurosis on the linea aspera (Pezzotta *et al.*, 2018). The diagnosis is based on clinical signs and symptoms in patients with a history of trauma, such as pain during palpation during contraction and stretching (Garvey *et al.*, 2010). However, an inaccurate diagnosis can lead to inadequate therapeutic interventions. Therefore, clinical examination should be supported by adequate radiological investigations, which allow early

identification and precise morphological description of the injury (Robinson *et al.*, 2011). Among all, musculoskeletal ultrasound has the advantage of dynamic acquisitions and can demonstrate edema and hematoma in the initial phase (Lorenzini *et al.*, 2008). Complete muscle ruptures, with discontinuity of all muscular tissue, are very rare. Subtotal muscle ruptures and tendon avulsions are more frequent. Injuries involving more than 50% of the muscle diameter, grade 3 injuries, usually have a similar healing time compared to complete injury (Mueller-Wohlfahrt *et al.*, 2013). This represents a longer rehabilitation time and more expenses for the soccer club. A previous study showed the effects of the scar acceleration method (M.A.C®) on a professional soccer player with grade 2 semitendinosus muscle injury. The athlete returned to training within a period of 5 days, while the return period with conventional physiotherapy treatment is usually 3 to 4 weeks, demonstrating an acceleration of the recovery time of the muscle tissue (Schlegel *et al.*,

2009; Pinto *et al.*, 2021). The M.A.C® is an innovative evaluation and treatment method, little disseminated in the literature, which is characterized by the evaluation of biomarkers and the use of photodynamic therapy. The aim of the present study was to report the course of a high-performance athlete with grade 3 injury in the right adductor muscle who received treatment with M.A.C®. The patient's consent has been obtained for this report. The case is being reported here for sharing with colleagues.

CASE REPORT

A 24-year-old patient, a soccer player for Fluminense Football Club for 2 years, on July 24th, 2021, during a match in the Brazilian professional soccer championship series A, reported pain in the right adductor region after jumping to dispute the ball. The patient was evaluated by the medical and off-field physiotherapist and attempted to return to the game, but did not feel able to continue and was substituted. On July 26th, 2021, two days after the injury, he was referred to the physiotherapy department with pain complaints in the long adductor region, edema, difficulty walking, and a pain level of 8 on the visual analog scale (VAS). The patient had no previous medical history of illnesses and was in good overall health. On the same day, an ultrasound of the adductor region was performed by the physiotherapist within the club, and subsequently, a magnetic resonance imaging (MRI) examination was conducted in an external clinic. Figures 1A and 1B show the patient's grade 3 injury on the second day after the injury on the MRI.

On clinical examination performed by the physiotherapist and physician, the patient presented marked edema in the medial thigh region and limping while walking. On the same day, physiotherapy treatment was initiated using M.A.C® in two sessions (morning and afternoon) until August 11th, 2021. On August 9th, 2021, the patient reported pain level 2 on the EVA scale. On August 10th, 2021, 15 days after starting M.A.C®, the patient was asymptomatic and showed improvement in musculoskeletal morphology, as assessed by ultrasound. The patient started transition/strengthening in the club's internal gym, with open chain strengthening exercises that did not involve the affected muscle groups for two days. This strengthening regimen included hip abductors, knee extensors and flexors, and the triceps surae. The patient also used the stationary bike. After starting the transition, the patient underwent a period of physiotherapy treatment and physical preparation.

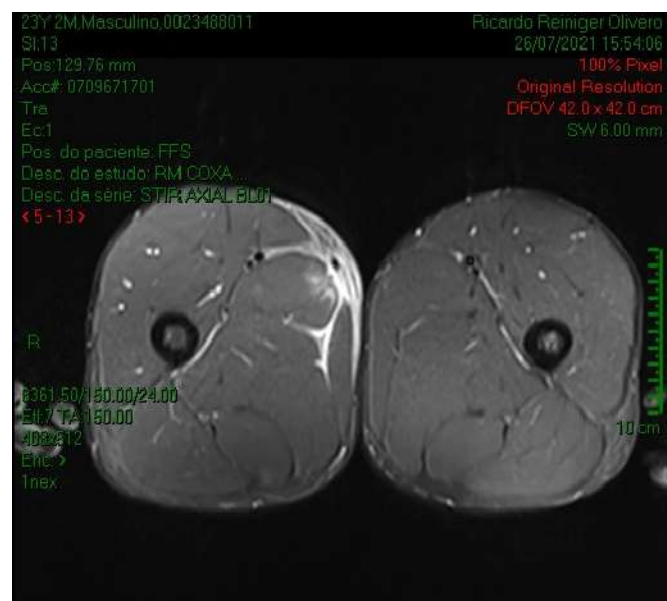


Figure 1A. The MRI report shows edema in the remaining muscle belly of the long adductor, associated with a band of fluid between the aponeuroses of this muscle, the adductor brevis, adductor magnus, and gracilis. There is significant edema in the subcutaneous tissue of the medial aspect of the upper third of the right thigh

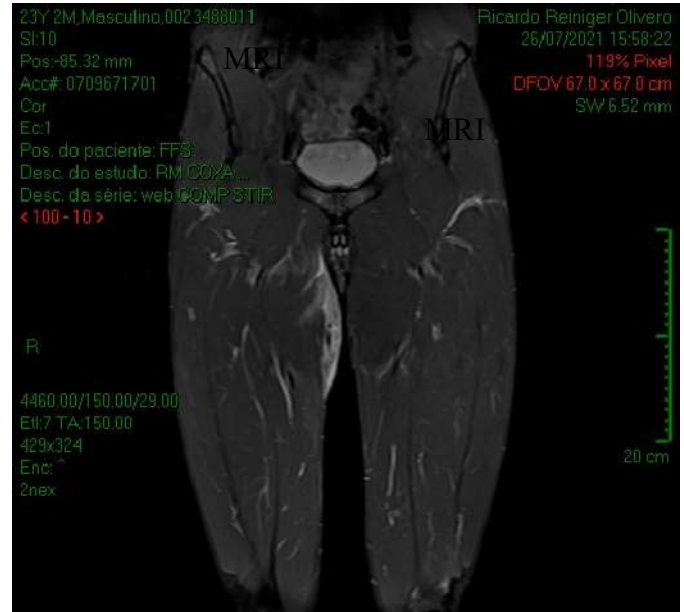

Figure 1B. It is evident the rupture of the myotendinous junction of the right long adductor muscle in a plane approximately 4 cm below the pubic symphysis, with irregularities of its fibers and a small hematoma in this location, measuring about 2 cm in diameter

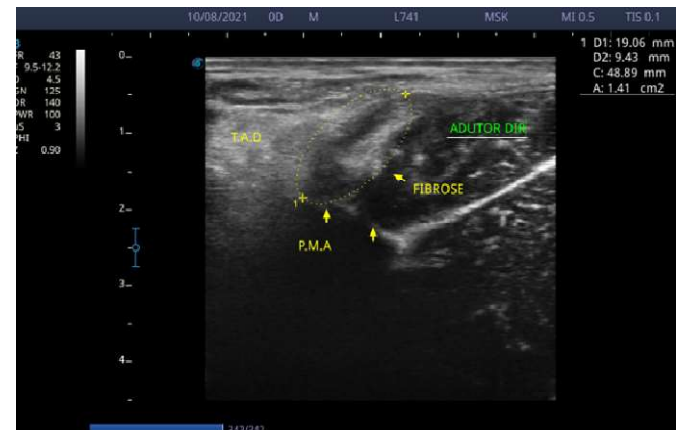


Figure 2 A. Ultrasound of the right long adductor muscle on August 10th, 2021

T.A.D - Right long adductor tendon. P.M.A - Myotendinous portion of the right long adductor. The arrow indicates an area of fibrosis in the myotendinous portion.

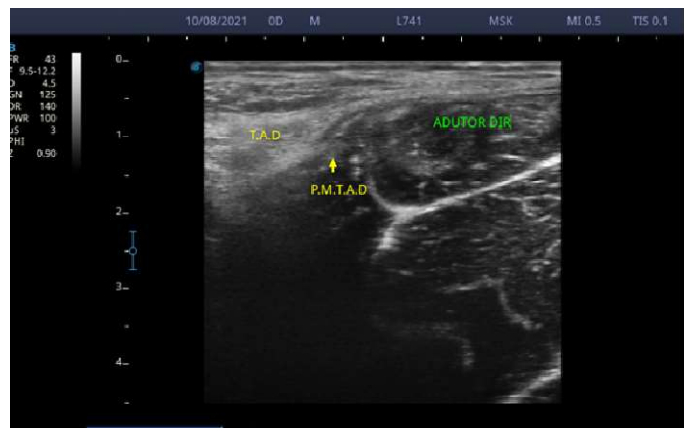


Figure 2. B–Ultrasound of the right long adductor muscle on August 10th, 2021

T.A.D - Right long adductor tendon. P.M.T.AD - Myotendinous portion of the right long adductor. The arrow indicates the myotendinous portion of the right long adductor.

On August 20, 2021, he had his last day of physiotherapy treatment using M.A.C ®, and was cleared for his first training session on the field with the transition professional, a physical educator. On August 27, 2021, a new ultrasound examination (Figure 3) was performed for control purposes. On August 28, 2021, he was cleared for his first unrestricted training session with the team. The athlete performed well on the field and did not experience any recurrence of injury or pain.

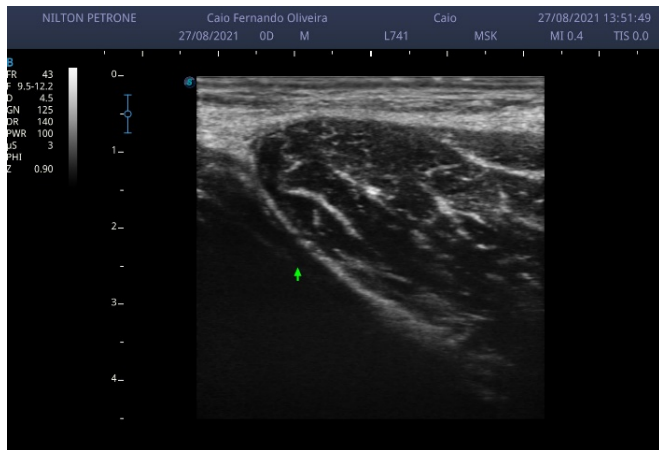


Figure 3. Ultrasonography image for evolutionary control of the long adductor injury on the 32nd day after injury

The arrow indicates the repaired region of the myotendinous portion of the right long adductor.

Return to play Adduction and abduction of maximal voluntary isometric contractions (AAMVIC): CF executed two previous AAMVIC tests for adductor injury (2020/07/27) and (2020/05/28) as routine physical department control for hip strength. After the injury treatment period, CF was evaluated again for the AAMVIC test to compare strength levels after treatment with strength levels before the injury. The comparison of strength levels between the injured and non-injured sides was also an objective of the evaluation. The following variables were used in the analysis: peak maximum force in the five repetitions, average of peak maximum force in the five repetitions, percentage of asymmetry for peak maximum force, and the ratio between the strength of adduction and abduction. ForceFrame® (Vald Performance, Queensland, Australia) was used for AAMVIC evaluation (Desmyttere *et al.*, 2019). The test was performed in a prone position, with the hip and knees flexed at 45°, with sensors placed on the medial femoral condyles. Verbal encouragement was given to ensure maximal contractions. Five isometric contractions were requested for adduction and abduction executed alternately, lasting 5 s each, with 10 s of rest between them.

Table 1. Describe results for AAMVIC pre and post adductor injurie

Date	Maximum Force (N)		Average Force (N)		Adductor / Abductor RATIO		Asymmetry index of average force (%)
	Left	Right	Left	Right	Left	Right	
2021/08/21	341.0	347.2	335.7	331.6	0.97	1.06	-1.2
2020/07/27	392.7	371.2	323.9	312.7	1.07	1.13	-3.4
2020/05/28	376.0	369.0	344.0	347.0	0.98	0.96	0.8

When look for force production result as parameter to understand if player could return to play at safe way and less reinjury risk, the asymmetric index could be the better parameter for that. Because, the against segment is the control, and at exception of injurie, it is in the

same training level. At the CF case, after injurie treatment, the asymmetric index reduced the average of force at five repetitions the 3.4% to 1.2% keeping the left side as more strong that right side, considered a not important change, if contextually at level 3 adductor injurie that the player did a few time ago. Considering the maximal force production was observed reduction of about 51 N for left side (not injured) and only 24 N for right side, based in this results the injured side lost less maximal force than another side, probably this results could be related a more attention at physical coach during strength training during RTP phase, in generally use more volume of training for side injured to compared the lost force after injuries. In contrast, after an injurie, CF increased the average of maximal force for five repetitions and could be associated a greater capacity of hip strength resistance, acquired after diary strength training routine for hip muscle at RTP period. Finally, at the adductor:abductor ratio is observed reduction for both sides, probably because was decreased for maximal force of adduction but not reduction for abduction.

Strength Test: In the strength test, there was a decrease in adductor strength bilaterally, with the right adductor (injured) maintaining higher levels of strength than the healthy adductor, but the difference between them is at acceptable levels (10%) for return to high-performance sports practice. Figure 4 shows the execution of the strength test.



Figure 4. Execution of the strength test

DISCUSSION

Our clinical practice shows that in general, athletes require 90 days of rehabilitation to return to full team practice without restrictions, and an additional 30 days to return to competitive level, totaling 120 days for the return to official competition. In the present case report, there was a reduction in the athlete's return period to the official game after 45 days between the date of injury and the date of the first game after recovery. The date of the game in which the injury occurred was July 24, 2021, and the athlete returned to play on September 7, 2021, playing for 65 minutes. Therefore, if we consider that an athlete who received conventional rehabilitation treatment takes around 2 months (60 days) to return to play, in the present case, there was a 25% reduction in the time for the return to official game. However, some athletes may take up to 120 days to return, resulting in a longer rehabilitation period, longer time out of official games, and increased costs for the club. In muscular injuries, return to play can take 1 to 2 weeks for minor injuries, 4 to 6 weeks for moderate injuries, and over 6 weeks for major and complete injuries (Pezzotta *et al.*, 2018).

Mechanism of action of photodynamic therapy - M.A.C®: The M.A.C® features an exclusive photodynamic therapy device with space/time folding emission of energy for tissue repair. According to research, photodynamic therapy enhances cellular metabolism through activation of the respiratory chain (Hamblin *et al.*, 2013). The M.A.C® device (photodynamic therapy) acts on cellular respiration, specifically in the mitochondrial cristae, and accelerates the electron transport, consequently accelerating the process of reactive oxygen species (ROS) production, where more singlet oxygen (1O_2) is produced, which is highly excitable oxygen, crucial for triggering biochemical actions and increasing ATP production. This is due to the method using unconventional optics in the use of lasers and LEDs. When the photon emission time is doubled, the cell responds because the stimulus is maintained without altering the peak power density speed, without decline or bio-inhibition. With daily ultrasound evaluation of the injury, it was observed that the M.A.C® was able to accelerate the repair in the injured muscle tissue.

CONCLUSION

The M.A.C® has been shown to be effective as part of a rehabilitation program for grade 3 adductor longus muscle injury in a high-performance soccer player, allowing the athlete to return to sports activities in a short period of time. This addresses the question raised by the scientific literature that classic rehabilitation programs for adductor longus muscle injury need to be revised due to the lack of consensus on the best methodology for athlete recovery and faster return to activity. This investigation suggests the need for a future randomized study, with a larger sample size, so that we can further deepen our contribution to the clinical intervention of the M.A.C® method. Preliminary results were promising for accelerating the healing of musculoskeletal tissue.

Acknowledgements: Acknowledgements to Brazilian company Ecco Fibras, represented by Mr. Henrique Trajano, for their scientific support in this article.

Conflict of Interest: The authors declare no conflict of interest regarding this article.

Funding: Not applicable.

REFERENCES

- Desmyttere G, Gaudet S, Begon M. 2019. Test-retest reliability of a hip strength assessment system in varsity soccer players. *Physical Therapy in Sport*. 37:138e143.
- Garvey, J.F.W., Read, J.W. & Turner, A. 2010. Sportsman hernia: what can we do?. *Hernia* 14, 17–25. doi.org/10.1007/s10029-009-0611-1
- Hamblin MR, Huang Y 2013. Handbook of photomedicine. 1st Edition. Published by CRC Press, Florida, EUA.
- Lorenzini C, Sofia L, Pergolizzi FP, Trovato M. 2008. Il valore dell'ecotomografia nell'identificazione dell'ernia inguinale occulta in pazienti con inguinodinia. *Chir Ital*. 60(6):813-7.
- Mueller-Wohlfahrt HW, Haensel L, Mithoefer K, Ekstrand J, English B, McNally S, Orchard J, Niek van Dijk C, Kerkhoffs GM, Schamasch P, Blottner, Swaerd L, Goedhart E, Ueblacker P. 2013 Terminology and classification of muscle injuries in sport: the Munich consensus statement. *Br.J. Sports Med*. 47:342-350.
- Pezzotta, G. Pecorelli A, Querques G, Biancardi S, Morzenti C, Sironi S (2018). MRI characteristics of adductor longus lesions in professional football players and prognostic factors for return to play. *Eur J Radiol*. 108: 52–58.
- Pinto MVM, Petrone N, Vilardi PJR, Petrone F, Sampaio AR, Fortuny E, Passos TPP, Mayer PF, Oliveira Junior MP, Baron MV 2021. Analysis of the m.a.c® healing acceleration methodology in a muscle injury. *International Journal of Development Research*. 11(11):51670-51675. doi: 10.37118/ijdr.23301.11.2021
- Robinson P, Bhat V, English B. 2011. Imaging in the assessment and management of athletic pubalgia. *Semin. Musculoskelet Radiol*;15(1):14-26. doi: 10.1055/s-0031-1271956.
- Schlegel TF, Bushnell BD, Godfrey J, Boublik M. 2009. Success of nonoperative management of adductor longus tendon ruptures in national football league athletes. *Am J Sports Med*. 37(7):1394-1399. doi:10.1177/0363546509332501
