



ISSN: 2230-9926


Available online at <http://www.journalijdr.com>

# IJDR

International Journal of Development Research

Vol. 13, Issue, 04, pp. 62534-62537, April, 2023

<https://doi.org/10.37118/ijdr.26640.04.2023>



RESEARCH ARTICLE

OPEN ACCESS

## A SIMPLE TECHNIQUE FOR HEMI EPIPHYSIODESIS IN CHILDREN USING MOSAICPLASTY SYSTEM

\*Dr. Anant Kumar Tiwari and Dr. Sanchay Lavaniya

Sir Gangaram Hospital New Delhi

### ARTICLE INFO

#### Article History:

Received 10<sup>th</sup> February, 2023

Received in revised form

11<sup>th</sup> March, 2023

Accepted 17<sup>th</sup> March, 2023

Published online 30<sup>th</sup> April, 2023

#### KeyWords:

Genu valgum, Guided growth, Mosaicplasty, Arthex OATS system.

#### \*Corresponding author:

Dr. Anant Kumar Tiwari

### ABSTRACT

Guided growth is helpful in correcting angular misalignments in children. Temporary and permanent hemiepiphysiodesis is a surgical procedure that can correct angular misalignments and provide effective correction. 12.5year old male with bilateral knee valgus deformity was included in this case study. Permanent hemiepiphysiodesis was performed using the Mosaicplasty system. Permanent hemiepiphysiodesis using the Arthex OATS System with a modification of the green approach is a safe and effective method for correcting knee valgus in adolescents.

Copyright©2023, Dr. Anant Kumar Tiwari and Dr. Sanchay Lavaniya et al. This is an open access article distributed under the Creative Commons Attribution License, which permits unrestricted use, distribution, and reproduction in any medium, provided the original work is properly cited.

Citation: Dr. Anant Kumar Tiwari and Dr. Sanchay Lavaniya. 2023. "A simple technique for hemi epiphysiodesis in children using mosaicplasty system". International Journal of Development Research, 13, (04), 62534-62537.

## INTRODUCTION

Knee valgus is part of a normal physiological process in children. During development, the femotibial (FT) angle changes from varus to valgus. Before the age of 1 year a child can reach varus up to 15 degree. By age 2 children are approaching neutrality. By age 3, children can develop maximum valgus before spontaneously improving to about 6° by age seven [1]. Persistent knee valgus can be unilateral or bilateral, with persistent knee valgus most commonly being bilateral. Etiologies such as cartilage growth disorders, skeletal dysplasia and idiopathic dysplasia are usually bilateral. Knee trauma or infection can lead to unilateral knee valgus. The indications for the procedure were: 1) unacceptable cosmetics; 2) Knee valgus > 15° after age 7; 3) asymmetry; 4) intermalleolar distance (MI) greater than 7.5 cm; 5) walking disorder; 6) pain and 7) decreased participation in physical activity [2,3]. Various surgical approaches have been described in the literature as effective treatments for patients with lower extremity angular deformities [4-9]. Physical manipulation has the advantage of reducing morbidity compared to more invasive methods such as osteotomy [10,11]. In 1933, Phemister described growth arrest by epiphyseal manipulation by rotating the epiphyseal plate 90° to create a bony bridge [12]. In 1949, Blount and Clarke described epiphyseal growth control by stapling the epiphyses [13]. Temporary hemi-epiphysiodesis can be performed with tension band plate plates, percutaneous pedicle screws, and staples [14-16].

The method described by Green, in which the growth plate is curetted anterior, posterior, and distal directions to the bone graft is made removed from the proximal holder and placed back in the original holder with the ends rotated 180 degrees. Timing of hemiepiphysiodesis for optimal cuff removal and deformity correction is key to success and is based on bone age radiographs [19-21]. In this study, we modified Green's technique by harvesting two 10mm bone blocks from the Arthex OATS system instead of using an osteotome for a single growth plate wedge in children with idiopathic valgus knee.

## METHODS

In order to determine the degree of deformity, IM distance measurements were made with the patient supine, legs flat and touching of the medial femoral condyles. An IM distance greater than 7.5cm was considered abnormal [2,3]. The FT angle was measured clinically preoperatively with AP radiographs and a goniometer to help guide the surgical procedure. Indications for surgery included pre-operative IM distance greater than 7.5cm and FT angles greater than 12° in addition to patient symptomatology. In our case the patient was having bilateral genu valgum deformity with tibiofemoral angle of right side was 14 degree and for left side it was 9.7 degree. Intermalleolar distance was more than 10 cm. Patient was given supine position on OT table. Both lower limbs were scrubbed,

Painted and draped. Under all aseptic conditions, incision was taken over the medial distal femoral site of size 4 cm which was 1 cm proximal to the joint line and in the center of the anterior and posterior aspect of femur. After dissection of subcutaneous tissues, periosteum was dissected and physis region of femur exposed. The physis region was identified with the help of a C-arm. Two bone blocks of 10 mm diameter with the depth of 15 mm were taken out keeping the physis in the center and reinserted with inner surface facing outwards as shown figure 5

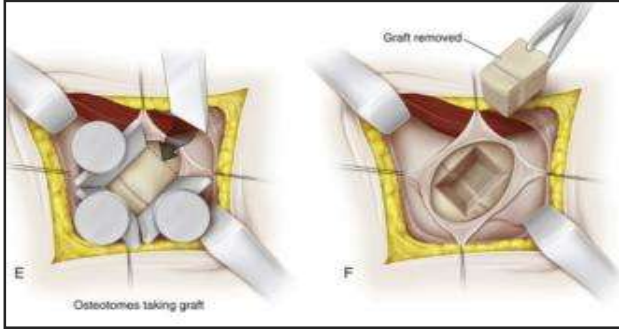


Figure 1 Green method

**Arthex Oats System:** Commonly used in Mosaicplasty for taking and transferring autologous osteochondral grafts from one site to another. 5 mm to 25 mm diameter sizes are available through which up to 25 mm cylindrical grafts can be taken out.

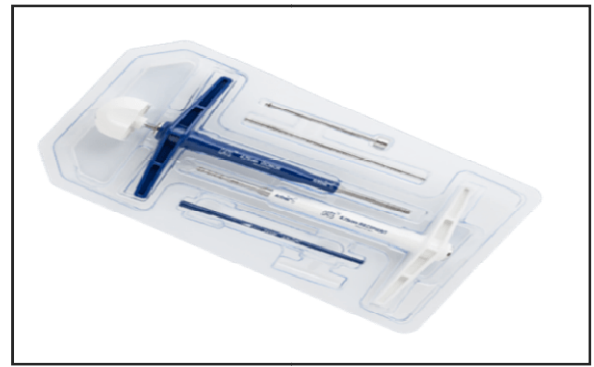


Figure 4. Arthex OATS system

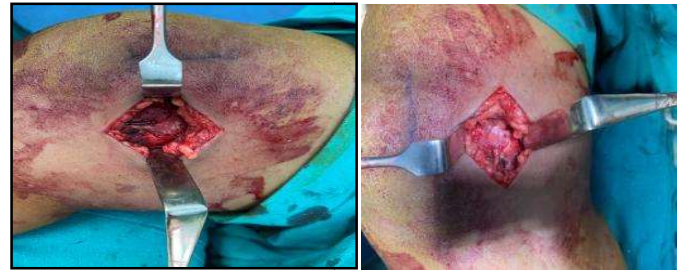

Figure 5.

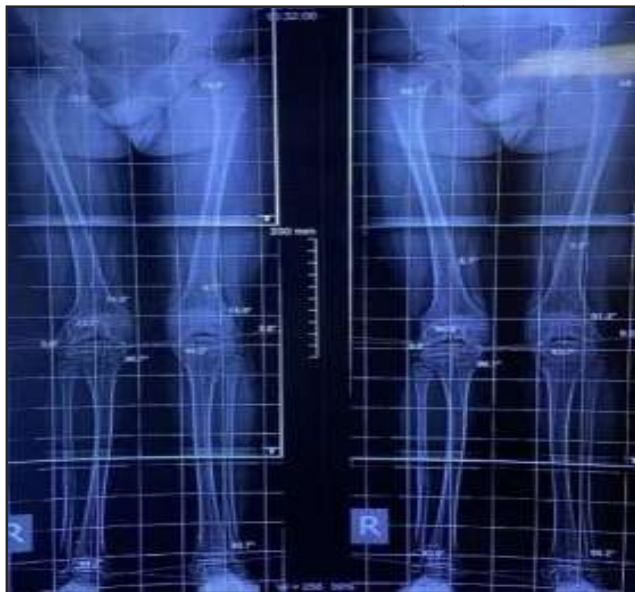

Figure 2. Pre op Radiograph

**Intra Operative Pictures:** Harvesting two bone block cylinders of 10 mm diameter with 15 mm length.

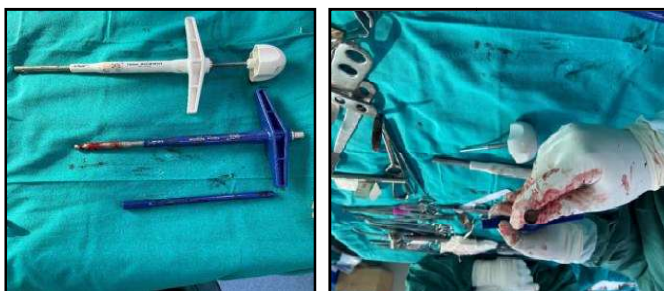

Figure 3.

**Intra op pictures:** Both cylinders are rotated 180 degree and reinserted at same site.

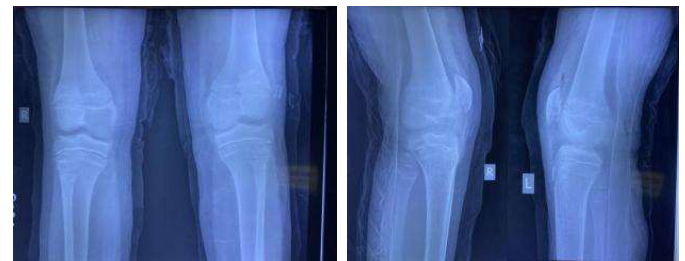
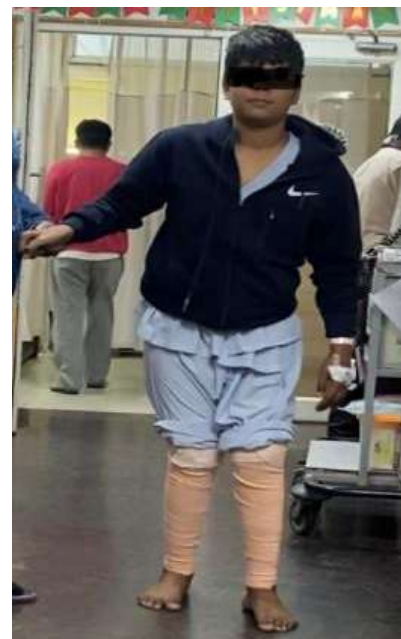
Figure 6. Post op radiograph

Patient was mobilised the next day of operation



## DISCUSSION

Medial hemiepiphysiodesis with a tubular bone block under fluoroscopy imaging is an effective treatment for adolescents with

idiopathic knee valgus. Inan [19] successfully corrected valgus by percutaneous hemi-epiphysiodesis in patients with a preoperative deformity of 12° and postoperative valgus measurements of 4°. Ferrick [22] showed an average mechanical axis correction of 10° with a FT manipulation correction factor of 1.1° per month over a one year period, Bowen [18] showed an average net correction of 1 angle FT of 4.4° for the physis, and another study [17] showed a sharp correction of the valgus angle of 11.8° FT by percutaneous hemi-epiphysiodesis. genu valgus has been shown to cause lateralization of the patella, making patients more prone to instability [23]. Patients who do not receive valgus correction may be at risk of failure due to persistent knee valgus and its significant association with patellar instability [24]. One of the keys to hemi-epiphysiodesis is the timing of the surgery. Lower limb growth has been shown to stop around 2 years and 6 months after distal phalangeal fusion in children [25, 26]. This may be the optimal time for patients to undergo permanent hemi-epiphysiodesis as their remaining growth phase begins to decrease and therefore relying on guided growth techniques may not be sufficient. Other studies analyzing the timing of onset of permanent hemi-epiphysiodesis have suggested surgery within 1-2 years after growth with careful follow-up [22].

Troyetal.investigated percutaneous epiphysiodesis with drill /curettage versus transphyseal screws [27] in 115 adolescents with leg length discrepancy (LLD). Both procedures showed equal efficacy in removing LLD with similar operative times and length of stay (LOS). However, the advantage of the drill curettage is that it does not usually need to return to the operating room for subsequent hardware removal [28,29]. Permanent hemi-epiphysiodesis using cylindrical bone blocks has several advantages over other methods of permanent epiphysiodesis. Extraction of the bone block with osteotomes sometimes causes bone deformities and sometimes late collapse of the medial condyle. This is a clean technique that allows clean bony cylinders to be removed without creating stress in the medial condyle. In addition, cylinders with a diameter of 5 mm to 20 mm and a depth of up to 25 mm can be removed and reversed without using force. Because there are no sharp corners, patient can be confidently told to bear full weight the day after surgery. This method requires no hardware removal and is less likely to cause postoperative infections. There is no rebound phenomena with this method. Cosmetically, the procedure is performed with minimal incision and minimal scarring and hardware is not needed [5,15,30]. We can use a horizontal incision to dissect the skin and a vertical incision to dissect the periosteum. The horizontal incision promotes better healing and the vertical incision helps provide more surface area for growth plate exposure and avoiding contact with deeper tissue with minimal incision.

## CONCLUSION

Permanent hemi epiphysiodesis using Arthex OATS system with cylindrical blocks from physis is a safe and effective method to correct genu valgum in adolescents. This procedure using using Arthex OATS system is easy to use, without much damage to physis and minimally invasive compare to the Green's procedure. Due to minimal invasive approach, there is less chances of post operative infections and less chances of adjoining tissue damage. Patient can confidently be asked to bear full weight after surgery.

## REFERENCES

Ballal MS, Bruce CE, Nayagam S. 2010. Correcting genu varum and genu valgum in children by guided growth: Temporary hemiepiphyseodesis using tension band plates. *J Bone Joint Surg Br* 92: 273-276.

Blair VP, Walker SJ, Sheridan JJ, Schoenecker PL. 1982. Epiphysiodesis: A problem of timing. *J Pediatr Orthop* 2: 281-284.

Blount WP, Clarke GR. 1949. Control of bone growth by epiphyseal stapling: A preliminary report. *J Bone Joint Surg Am* 31: 464-478.

Bowen JR, Leahey JL, Zhang ZH, MacEwen GD. 1985. Partial epiphysiodesis at the knee to correct angular deformity. *Clin Orthop Relat Res* 198: 184-190.

Bowen RJ, Johnson WJ. 1983. Percutaneous Epiphysiodesis. *Clin Orthop Relat Res* 190: 170-173.

Bowen RJ, Torres RR, Forlin E. 1992. Partial epiphysiodesis to address genu varum or genu valgum. *J Pediatr Orthop* 12: 359-364.

Brauwer VD, Moens P. 2008. Temporary hemiepiphyseodesis for idiopathic genua valga in adolescents: Percutaneous Transphyseal Screws (PETS) versus stapling. *J Pediatr Orthop* 28: 549-554.

Burghardt RD, Herzenberg JE. 2010. Temporary hemiepiphyseodesis with the eight-Plate for angular deformities: Mid-term results. *J Orthop Sci* 15: 699-704.

Dimeglio A. 2001. Growth in pediatric orthopaedics. *J Pediatr Orthop* 21: 549-555.

Ferrick MR, Birch JG, Albright M. 2004. Correction of non-Blount's angular knee deformity by permanent hemiepiphyseodesis. *J Pediatr Orthop* 24: 397-402.

Fraser RK, Dickens DR, Cole WG. 1995. Medial physeal stapling for primary and secondary genu valgum in late childhood and adolescence using transphyseal screws (PETS). *J Bone Joint Surg Br* 77: 733-735.

Frosch KH, Schmeling A. 2016. A new classification system of patellar instability and patellar maltracking. *Arch Orthop Trauma Surg* 136: 485-497.

Gottlieb M, Rahbek O, Hvid I, Davidsen M, Hellfritsch MB, et al. 2013. Hemiepiphyseodesis: Similar treatment time for tension-band plating and for stapling: A randomized clinical trial on guided growth for idiopathic genu valgum. *Acta Orthop* 84: 202-206.

Howorth B. 1971. Knock knees. With special reference to the stapling operation. *Clin Orthop Relat Res* 77: 233-246.

Inan M, Chan G, Bowen JR. 2007. Correction of angular deformities of the knee by percutaneous hemiepiphyseodesis. *Clin Orthop Relat Res* 456: 164-169.

Kelly PM, Dimeglio A. 2008. Lower-limb growth: How predictable are predictions? *J Child Orthop* 2: 407-415.

Kling TF, Hensinger RN. 1983. Angular and torsional deformities of the lower limbs in children. *Clin Orthop Relat Res* 176: 136-147.

Maase P, Zreik H. 1985. Can one determine the age at which epiphysiodesis should be performed in the treatment of genu valgum in the adolescent? *Rev Chir Orthop Reparatrice Appar Mot* 71: 319-325.

McWalter EJ, Cibere J, Macintyre NJ, Nicolaou S, Schulzer M, et al. 2007. Relationship between varus-valgus alignment and patellar kinematics in individuals with knee osteoarthritis. *J Bone Joint Surg Am* 89: 2723-2731.

Metaizeau JP, Wong-Chung J, Bertrand H, Pasquier P (1998) Percutaneous Epiphysiodesis using Transphyseal Screws (PETS). *J Pediatr Orthop* 18: 363-369.

Nouh F, Kuo LA. 2004. Percutaneous epiphysiodesis using transphyseal screws (PETS): Prospective case study and review. *J Pediatr Orthop* 24: 721-725.

Park H, Park M, Kim SM, Kim HW, Lee DH. 2018. Hemiepiphyseodesis for idiopathic genu valgum: Percutaneous transphyseal screw versus tension-band plate. *J Pediatr Orthop* 38: 325-330.

Phemister DB. 1933. Operative arrestment of longitudinal growth of bones in the treatment of deformities. *J Bone Joint Surg Am* 15: 1-15.

Pistevos G, Duckworth T. 1977. The correction of genu valgum by epiphyseal stapling. *J Bone Joint Surg Br* 59: 72-76.

R Core Team. 2018. R: A language and environment for statistical computing. R Foundation for Statistical Computing, Vienna, Austria.

Salenius P, Vankka E. 1975. The development of the tibiofemoral angle in children. *J Bone Joint Surg Am* 57: 259-261.

Scott AC, Urquhart BA, Cain TE. 1996. Percutaneous vs. modified phemister epiphysiodesis of the lower extremity. *Orthopedics* 19: 857-861.

Troy M, Shore B, Miller P, Mahan S, Hedequist D, et al. 2018. A comparison of screw versus drill and curettage epiphysiodesis to correct leg-length discrepancy. *J Child Orthop* 12: 509-514.

Volpon JB. 1997. Idiopathic genu valgum treated by epiphysiodesis in adolescence. *Int Orthop* 21: 228-231.

Zuege RC, Kempken TG, Blount WP. Epiphyseal stapling for angular deformity at the knee. *J Bone Joint Surg Am* 61: 320-329.

\*\*\*\*\*