



ISSN: 2230-9926

Available online at <http://www.journalijdr.com>

IJDR

International Journal of Development Research

Vol. 13, Issue, 08, pp. 63542-63548, August, 2023

<https://doi.org/10.37118/ijdr.27136.08.2023>



REVIEW ARTICLE

OPEN ACCESS

MANAGEMENT OF CHILDREN AFFLICTED WITH HIRSCHSPRUNG'S DISEASE: A NARRATIVE REVIEW

Geovana Thees Perillo Rodrigues*¹, Mariana Thees Perillo Rodrigues², Maria Luiza Pimentel de Oliveira³, Izabella Sena de Oliveira³ and André Luis de Aquino Carvalho¹

¹Unidade de Cirurgia Geral, Hospital Regional da Asa Norte - HRAN, Secretaria de Estado de Saúde do Distrito Federal - SES/DF, Setor Médico Hospitalar Norte, Quadra 101, Bloco A, Área Especial - Brasília-DF, Brasil

²Unidade de Pediatria, Hospital Materno Infantil de Brasília - HMIB, Secretaria de Saúde do Distrito Federal

³Faculdade de Ciências e Educação em Saúde, Centro Universitário de Brasília. 707/907 Asa Norte, Brasília, Brasil

ARTICLE INFO

Article History:

Received 11th May, 2023

Received in revised form

16th June, 2023

Accepted 08th July, 2023

Published online 30th August, 2023

KeyWords:

Hirschsprung disease,
Surgical treatment.

*Corresponding author:

Geovana Thees Perillo Rodrigues

ABSTRACT

Introduction: Hirschsprung's disease is a genetic anomaly with an incidence of 1 in 5000 births, predominantly affecting females at a ratio of 1:4. It is characterized by the absence of ganglion cells in the enteric nervous system in the distal segment of the gastrointestinal tract. Approximately 90% of individuals with Hirschsprung's disease present with symptoms in the neonatal period. Classic symptoms include abdominal distension (>90%), vomiting (>85%), which can be bilious, and the absence of meconium passage in the first 24 hours of life (>60%). Diagnosis is established through biopsies (gold standard), contrast enema, and anorectal manometry. While awaiting the results of rectal biopsy, saline rectal irrigations should be initiated one to three times daily to achieve functional bowel obstruction relief and enable enteral feeding until the pull-through operation. There are many surgical approaches for Hirschsprung's disease, including transabdominal approach (TAB) and transanal pull-through (TERPT). TAB mainly includes Swenson, Duhamel, Duhamel and Soave techniques. Swenson involves the removal of the affected area entirely with a termino-terminal anastomosis to the anal canal. In Duhamel, the normal colon is usually brought through the posterior rectal space and anastomosed with the contralateral rectum. In Soave, saline is injected into the rectum after circularly cutting the rectal muscular layer, leaving the mucosa intact at the level of the dentate line. Later, De La Torre-Mondragon proposed a new treatment called single-stage TERPT, a minimally invasive surgery with an anal approach that eliminates abdominal adhesions and pelvic nerve injury. The most commonly performed operation is the Duhamel procedure. The benefits of Duhamel include decreased stool frequency and increased consistency, but they must be balanced with the risk of pouch dilation and stool stasis. TERPT is superior to TAB in terms of hospital stay and constipation. However, there are still a large number of randomized studies to be verified, and more trials are expected to be conducted in the future to determine the best surgery. Among the postoperative complications are enterocolitis, dermatitis, fecal incontinence, and obstruction, with enterocolitis having the highest morbidity and mortality. Alternative treatments, although lacking evidence to prove their efficacy, include botulinum toxin, probiotics, and laser therapy. **Objective:** To synthesize the main and most up-to-date knowledge on the management of children with Hirschsprung's disease, from diagnosis to definitive treatment. **Methods:** This study is a narrative review. To carry out this work, systematic reviews, meta-analyses, and cohort studies published in the last five years (2018 to 2022) were searched in the PUBMED scientific database. The keywords used were "Hirschsprung disease" and "Surgical treatment." Sixteen articles were found in the database.

Copyright©2023, Geovana Thees Perillo Rodrigues et al. This is an open access article distributed under the Creative Commons Attribution License, which permits unrestricted use, distribution, and reproduction in any medium, provided the original work is properly cited.

Citation: Geovana Thees Perillo Rodrigues, Mariana Thees Perillo Rodrigues, Maria Luiza Pimentel de Oliveira, Izabella Sena de Oliveira and André Luis de Aquino Carvalho. 2023. "Management of children afflicted with hirschsprung's disease: A narrative Review". *International Journal of Development Research*, 13, (08), 63542-63548.

INTRODUCTION

Hirschsprung's disease is a genetic anomaly with an incidence of 1 in 5000 births (GONG, Yun-Ying, 2022), with a female predominance of 1 in 4 (KYRKLUND, Kristiina 2020). It is characterized by the absence of ganglion cells in the enteric nervous system in the distal segment of the gastrointestinal tract (GONG, Yun-Ying, 2022). The absence of these cells in both the submucosa (Meissner) and the

myenteric plexus (Auerbach) results in abnormally tonic contraction of the colon (KYRKLUND, Kristiina, 2020). The genetic alterations are complex and involve coding and non-coding DNA, influenced by combined effects of mutations in over 30 different genes (VERKUIJL, Sanne, 2021). Non-syndromic or isolated Hirschsprung's disease accounts for 70% of affected children, while approximately 30% of affected children have associated chromosomal anomalies (12%) and/or congenital conditions (18%). The presence of

Down syndrome increases the risk of Hirschsprung's disease by 50 to 100 times (AMBARTSUMYAN, Lusine, 2020). In around 80% of patients, the aganglionic segment is located in the rectosigmoid area, while in 3% to 10% of cases, the entire colon is aganglionic (total colonic aganglionosis), and in a small minority, aganglionosis extends into the proximal small intestine (AMBARTSUMYAN, Lusine, 2020). Despite diagnostic advancements, mortality rates of 2% to 5% are still reported. The current method for confirming aganglionosis involves contrast enema, anorectal manometry, and rectal biopsies, with the latter considered to have the highest diagnostic specificity (AMBARTSUMYAN, Lusine, 2020). Surgical resection of the affected segment remains the gold standard treatment for Hirschsprung's disease. Even after surgical treatment, it can take years for patients to acquire normal bowel function and continence (AMBARTSUMYAN, Lusine, 2020). Furthermore, patients are at risk of disease-specific long-term issues, including persistent constipation (11%-16%), fecal soiling or incontinence (7%-48%), or recurrent enterocolitis episodes (0%-33%) (KAPUR, 2020). Children with Hirschsprung's disease experience a significant reduction in quality of life, facing negative impacts on their social life, emotional well-being, and engagement in physical activities. Moreover, these complications contribute to increased social morbidity during childhood, associated with elevated levels of anxiety and depression (AMBARTSUMYAN, 2020).

General Objective

- To synthesize the primary and most up-to-date knowledge regarding the management of children with Hirschsprung's Disease, from its diagnosis to definitive treatment.

Specific Objectives

- Early diagnosis of Hirschsprung's Disease
- Preferred surgical procedure for treating Hirschsprung's Disease
- Postoperative complications in Hirschsprung's Disease

DISCUSSION

Clinical Presentation: Approximately 90% of individuals with Hirschsprung's Disease (HD) exhibit symptoms during the neonatal period. Classic symptoms include abdominal distension (>90%), vomiting (>85%) that can be bilious, and failure to pass meconium within the first 24 hours of life (>60%). After digital rectal examination or the passage of a rectal tube, there is typically a release of gas and feces, which can be explosive and malodorous (KYRKLUND, 2020). Intestinal perforation of the cecum, ascending colon, or appendix may be the presenting symptom in up to 5% of neonates with HD (AMBARTSUMYAN, 2020). In recent years, approximately 14% of cases were premature births (KYRKLUND, 2022).

Diagnosis: Two available screening tests for the diagnosis of HD are contrast enema (CE) and anorectal manometry (ARM). It is recommended that patients with findings suggestive of HD undergo rectal suction biopsy (RSB). If RSB results are inconclusive, a full-thickness biopsy is recommended (AMBARTSUMYAN, Lusine, 2020).

Biopsy: Surgical resection of the aganglionic segment remains the gold standard treatment for Hirschsprung's Disease. The surgical objective is to resect the aganglionic intestine and pull through the intestinal segment containing a normal enteric nervous system. Therefore, it's important to intraoperatively determine the location of ganglion cells. This is typically achieved through neuropathological review of a frozen biopsy of the entire intestinal circumference during open surgery or multiple biopsies during laparoscopic surgery (VERKUIJL, Sanne, 2021). Intraoperative frozen sections are extremely important, first to confirm the presence of ganglion cells and later to exclude features of the transition zone (partial circumferential aganglionosis, hypoganglionous myenteric plexus,

and submucosal nerve hypertrophy) at the proximal surgical margin (anastomotic). Any of these findings is considered diagnostic of the transition zone and an indication for positioning the enterostomy/anastomosis more proximally in the intestine (SMITH, Caitlin, 2020). Postoperative histopathological analysis of resection specimens should be adapted to document distal aganglionosis, the length of the aganglionic segment, its proximity to the anastomotic margin, and confirm complete resection of the transition zone. Recognizing or excluding ganglion cells is the primary aim of a leveling biopsy. If the pathologist cannot confidently arrive at a frozen section diagnosis, obtaining real-time opinions from colleagues, if available, is prudent. If uncertainty persists, the surgeon needs to be made aware of the diagnostic dilemma, and another biopsy, perhaps more generous than the first, should be considered. Ongoing uncertainty can be a good reason to delay bowel resection, obtain biopsies from various locations, perform a diversion ostomy at a level deemed likely to contain ganglion cells based on macroscopic or radiographic findings, and allow time for permanent sections of biopsies before the pull-through surgery is performed (SMITH, Caitlin, 2020). If, during the biopsy process, ganglion cells are not identified, and there is concern for total colonic aganglionosis, appendix biopsy should not be performed as it can be misleading, as repeatedly reported in the literature. Appendiceal aganglionosis is not a reliable index of total colonic aganglionosis because a skip area (areas with intact ganglion cells, interrupting an otherwise long aganglionic segment) may exist in other parts of the colon. Appendectomy should also be avoided as the appendix can serve as a useful conduit for antegrade enemas in patients with severe persistent symptoms after a pull-through procedure. An ileal or small intestine biopsy is favored and should be performed instead of appendix sampling for this reason (SMITH, Caitlin, 2020).

Rectal suction biopsy is the most common diagnostic approach for HD. An adequate biopsy contains sufficient submucosa to rule out submucosal ganglion cells with comprehensive histological assessment. While rectal suction biopsies are generally reliable, limitations include uncertainty about the precise location of the biopsy site in relation to the lower end of the rectum and potential for inadequate sampling. Incisional biopsy is an alternative that requires anesthesia but is site-specific by direct visualization, reliably yielding a generous submucosal sample and can be deep enough for sampling the muscularis propria and myenteric plexus (VERKUIJL, Sanne, 2021). The most widely employed techniques to identify ganglion and aganglionic intestinal segments are hematoxylin and eosin (H&E) staining and histochemical acetylcholinesterase (AChE) staining. Increased AChE expression is associated with hypertrophied extrinsic nerve fibers in the aganglionic segment in most HD patients. With AChE staining, false negatives are primarily related to age, and absence of an AChE reaction does not reliably exclude HD in very young neonates (KYRKLUND, Kristiina, 2020). The presence of any number of ganglion cells in H&E staining rules out HD. However, H&E staining has limitations in visualizing ganglion cells, particularly in neonates and premature babies, where these cells can be small and immature. If ganglion cells are not observed, additional staining with calretinin and/or peripherin immunohistochemistry is advisable before diagnosing HD (KYRKLUND, Kristiina, 2020). Enzymatic histochemical techniques for ganglion cell detection are also currently employed, such as lactate dehydrogenase (LDH), nicotinamide adenine dinucleotide (NADH) reactions, reduced tetrazolium, and/or succinate dehydrogenase (SDH) (KAPUR, Raj, 2020). Most ganglion cells stain using any of these three enzyme techniques. Therefore, negative staining for LDH, NADH, and/or SDH is an additional indication of aganglionosis. In general, it's argued that the dissection level should be at least five centimeters proximal to the biopsy site where ganglion cells have been confirmed to ensure ganglionic bowel will be pulled through. However, the transition zone may extend further in patients with a longer aganglionic segment, requiring a longer resection margin (MEI, Fan, 2022). Biopsies should be performed at a minimum of 2 cm above the dentate line to avoid the physiological aganglionic/hypoganglionic zone of the distal rectum, with at least 3 cm of distance, and one-third

of the sample should include submucosa (KYRKLUND, Kristiina, 2020).

Contrast Enema: In contrast to ARM, contrast enema (CE) is widely available in most centers but requires an experienced radiologist to accurately perform and interpret the study. During a CE, water-soluble contrast is instilled into the colon through a catheter inserted into the anus, followed by live fluoroscopic imaging (AMBARTSUMYAN, Lusine, 2020). Findings suggestive of HD include the presence of a radiographic transition zone (TZ) with dilated proximal bowel, microcolon, contrast retention on post-evacuation film, irregular colonic contractions, mucosal irregularities, or a sawtooth pattern in the rectum and abnormal rectosigmoid ratio (SMITH, 2020 and AMBARTSUMYAN, Lusine, 2020). The rectosigmoid ratio, calculated as the diameter of the rectum divided by the sigmoid colon during CE, is normally greater than 1. A value below 1 suggests HD. The radiographic location of the TZ correlates with the length of the aganglionic segment, specifically the rectosigmoid segment, and can aid in surgical planning (AMBARTSUMYAN, Lusine, 2020). However, the correlation was lower in segments proximal to the rectosigmoid and in infants younger than 3 months. Müller et al. reported an overall agreement of 58.1% ($\kappa=0.39$) between the TZ and the extent of aganglionosis in their cohort of 79 HD patients. This is particularly important when planning a transanal pull-through versus a combined abdominal and perineal pull-through approach (SMITH, Caitlin, 2020). In patients with long-segment HD, especially those with total colonic aganglionosis (TCA), the TZ can be falsely or inaccurately reported, resulting in delayed diagnosis and treatment. Additionally, the use of an enema, irrigation, or rectal examination to decompress the distal colon before a CE and inflation of a balloon on the catheter used to instill the contrast can distort the TZ and lead to inaccurate results (AMBARTSUMYAN, Lusine, 2020).

Anorectal Manometry: Anorectal manometry (ARM) is used to assess the voluntary and involuntary properties of the anorectal canal. It is less invasive than a rectal biopsy and, unlike CE, does not require exposure to radiation. The performance and interpretation of ARM require skill and knowledge from the operator and expertise that is only available in selected gastrointestinal motility reference centers. Patient cooperation is essential for accurate testing, but sedation or anesthesia can be used for children who may not cooperate during the study. The choice of sedation is crucial, as it can affect the rectoanal inhibitory reflex (RAIR) or decrease intra-anal pressures, leading to difficulty assessing the RAIR. During ARM, a flexible catheter with a latex-free balloon at its distal end is introduced into the rectum. Sensors spaced at predetermined intervals along the catheter shaft allow continuous measurement of intra-anal pressures during the study. Manometric assessment of anorectal function includes measurement of anal canal length and resting pressures, RAIR, rectal sensation, and finally, the ability to squeeze and simulate defecation. RAIR is the reflex relaxation of the lower anal sphincter (IAS) in response to rectal distension. This reflex is present in individuals with normal intrinsic gut innervation and absent in those with HD. The North American Society for Pediatric Gastroenterology, Hepatology, and Nutrition recommends ARM as the initial screening test for HD in centers with manometric capability. If ARM results are consistent with or suggestive of HD, the patient is referred for rectal biopsy. In a systematic review by Lorijn et al., they compared the diagnostic accuracy of ARM, CE, and rectal suction biopsy (RSB) in infants suspected of having HD. They reported that RSB was the most accurate test with the highest average sensitivity of 93% and average specificity of 98%, while ARM was 91% and 94%, respectively. ARM is considered the preferred screening test for HD, and a positive test should be confirmed with RSB (AMBARTSUMYAN, Lusine, 2020).

Surgical Treatment

Preoperative Care: While waiting for the results of the rectal biopsy, saline rectal irrigations should be initiated one to three times a day to achieve functional bowel obstruction relief and allow enteral feeding

until the pull-through operation. These irrigations are effective in approximately 75% of cases. Irrigation failure is related to total or extended aganglionosis. In colorectal surgery, a single dose of antibiotics with coverage against aerobic and anaerobic bacteria has shown to reduce postoperative wound infections by 75% (KYRKLUND, Kristiina, 2020).

Surgical Techniques: Surgical resection of the aganglionic segment remains the gold standard treatment for Hirschsprung's disease (MEI, Fan, 2022). The goal of a pull-through procedure is to remove the aganglionic colon segment, bring the normally innervated intestine down to the anus, and preserve anal sphincter function (MAO, Yong-zhong, 2019). There are various surgical approaches for Hirschsprung's disease, including the transabdominal approach (TAB) and transanal endorectal pull-through (TERPT). The TAB approach mainly includes the Swenson (peri-rectal), Duhamel (posterior rectal), and Soave (endorectal) procedures (YAN, Bei-lei, 2019). In the Swenson procedure, an abdominal incision and extra-mucosal biopsies are made along the antimesenteric border and evaluated by frozen section to determine the level of ganglionated intestine (MAO, Yong-zhong, 2018). During the operation, the entire affected site is removed, and a termino-terminal anastomosis of the normal colonic anal canal is performed (YAN, Bei-lei, 2019). The Duhamel procedure involves a retrorectal transanal pull-through method and does not require rectal resection. The posterior wall of the rectum and the anterior wall of the pulled-down colon are opposed by a crushing clamp, resulting in a wide anastomosis. Thus, a section of aganglionic rectum is left connected to a segment of ganglionated colon (side-to-side) as a reservoir pouch (MAO, Yong-zhong, 2018). The Duhamel procedure was designed to prevent potential injuries to pelvic and anal canal structures by eliminating anterior rectal dissection. However, by leaving a significant amount of aganglionic intestine, complications such as persistent obstructive symptoms and constipation are observed (YAN, Bei-lei, 2019). The Soave technique involves removing the rectal mucosa while preserving the muscle cuff, and a ganglionated segment of the colon is anastomosed to the mucosa of the anal canal. Normal saline is injected into the rectum after circularly cutting the rectal muscular layer, keeping the mucosa intact up to the dentate line (YAN, Bei-lei, 2019). In 1998, Dela Torre-Mondragon proposed a new treatment called single-stage TERPT, which is more suitable for infants. The transanal endorectal pull-through (TERPT) was originally a transanal submucosal dissection similar to Soave with an endorectal pull-through, leaving an aganglionic rectal muscle cuff. The procedure was modified into a transanal operation similar to Swenson, where submucosal plane dissection is not required. Instead, a full-thickness resection of the colon above the dentate line is used (ALLIN, Benjamin, 2022). Laparoscopy can be used for locating the transition zone and mobilizing the distal aganglionic sigmoid colon (MAO, Yong-zhong, 2018). This minimally invasive surgery with an anal approach has become an increasingly popular method for treating Hirschsprung's disease, eliminating the risk of complications like abdominal adhesions and pelvic nerve injury (YAN, Bei-lei, 2019).

In 2000, Georgeson et al. described a new laparoscopically assisted anorectal pull-through (LAARP) technique. The procedure involves minimal perineal dissection, preservation of the distal rectum, and precise placement of the rectum within the levator ani muscle and external anal sphincter. In recent decades, the major advancements in Hirschsprung's disease surgery have been the shift toward primary repairs rather than two- or three-stage procedures, as well as the use of laparoscopic and transanal techniques. Currently, the Duhamel pull-through and endorectal pull-through are the most commonly performed procedures, with no clear preference for one of these techniques in terms of complications and outcomes (VERKUIJL, Sanne, 2021). In the meta-analysis by Bei-lei Yan et al., postoperative complications of TAB and TERPT were compared. A total of 87 studies were analyzed, involving 724 patients, including 392 cases of TERPT and 332 cases of TAB. TERPT had a shorter postoperative hospital stay [mean difference (MD) = -6.74 days; 95% CI: -13.26 to -0.23; P = 0.04] and a lower incidence of postoperative incontinence (OR = 0.54; 95% CI: 0.35–0.83; P = 0.006) and constipation (OR =

0.50; 95% CI: 0.28–0.90; $P = 0.02$). There was no difference in the duration of surgery (MD = -30.59 min; 95% CI: -98.01 to 36.83; $P = 0.37$) and the incidence of postoperative enterocolitis (OR = 0.78; 95% CI: 0.53–1.17; $P = 0.53$) (YAN, Bei-lei, 2019). In the meta-analysis by Yong-zhong Mao et al., the results of treatment using the surgical procedures of Duhamel or TERPT were compared. The study included six studies with a total of 280 patients. In all of them, both procedures were associated with good to complete continence. The reported rate of constipation ranged from 0% to 59%, with the highest rate often observed with the Duhamel technique. The operation time for the Duhamel method varied from 154 to 257 minutes, and for the TERPT method, it ranged from 120 to 232 minutes. The postoperative hospitalization time ranged from 4.3 to 17 days for the Duhamel technique and from 4 to 17 days for the TERPT procedure. When reporting the number of patients with enterocolitis, it ranged from 1 to 2 patients in one study for the Duhamel method and from 0 to 13 patients for the TERPT method. The meta-analysis indicated that the Duhamel and TERPT interventions were similar in terms of postoperative fecal incontinence rate (OR = 0.85, 95% CI = 0.37 to 1.92, $P = 0.692$) and operation time (mean difference = 46.68 minutes, 95% CI = -26.96 to 114.31, $P = 0.226$). The Duhamel procedure was associated with longer postoperative hospitalization (mean difference = 3.14 days, 95% CI = 1.46 to 4.82, $P < 0.001$) and a lower rate of enterocolitis (OR = 0.21, 95% CI = 0.07 to 0.68, $P = 0.009$) compared to the TERPT procedure (MAO, Yong-zhong, 2018).

In the study by Shogo Seo et al., seven observational clinical studies were conducted, comprising 260 cases of Duhamel pull-through and 170 cases of TERPT. Anastomotic stenosis (OR = 0.10; 95% CI 0.02–0.48; $p = 0.004$) was lower after Duhamel pull-through than after TERPT. There were no significant differences in the incidence of postoperative incontinence/soiling and anastomotic leakage. Following TERPT, postoperative constipation appears to be lower and enterocolitis higher compared to those after Duhamel pull-through. However, these differences are not significant when the follow-up period is equal between the groups. It was concluded that Duhamel pull-through seems to be associated with a lower incidence of anastomotic stenosis compared to TERPT. The effects of the two operative techniques on constipation and enterocolitis remain unclear. The quality of evidence supporting the above findings is below ideal, indicating the need for prospective studies (MAO, Yong-zhong, 2018). In a prospective cohort study by Benjamin S R Allin et al., the outcomes in primary school-aged children with Hirschsprung's disease (HD) were compared after Soave, Duhamel, or Swenson procedures. Out of 305 children, 277 (91%) underwent pull-through surgery (53% Soave, 37% Duhamel, 9% Swenson). Based on 259 children (94%) with complete operative data, the rates of unplanned reoperation (95% CI) were 0.11 (0.08–0.13), 0.34 (0.29–0.40), and 1.06 (0.86–1.31) in the Soave/Duhamel/Swenson groups, respectively. Adjusted Hazard Ratios for unplanned reoperation compared to Soave were 1.50 (95% CI 0.66–3.44, $p = 0.335$) and 7.57 (95% CI 3.39–16.93, $p < 0.001$) for Duhamel/Swenson, respectively. Among 217 children with 5–8 years of post-pull-through follow-up, 62%, 55%, and 62% in the Soave/Duhamel/Swenson groups reported fecal incontinence. Compared to Soave, Duhamel was associated with a lower risk of fecal incontinence (aOR 0.34, 95% CI 0.13–0.89, $p = 0.028$). Among 191 children without a stoma, 42%, 59%, and 30% in the Soave/Duhamel/Swenson groups required assistance to maintain bowel movements; compared to Soave, the Duhamel group was more likely to require assistance (aOR 2.61, 95% CI 1.03–6.60, $p = 0.043$). In this study, it was concluded that compared to Soave, Swenson was associated with an increased risk of unplanned reoperation, while Duhamel was associated with a reduced risk of fecal incontinence but increased the risk of constipation at 5–8 years of age. The described risk profiles can be used to inform consent discussions between surgeons and parents (ALLIN, Benjamin, 2022).

Single-Stage vs. Two-Stage Approach: The choice between a single-stage and a two-stage surgical intervention is determined by clinical instability (enterocolitis), intestinal dilation, and the location of the transition zone. While enterocolitis can often be managed with rectal

irrigations, antibiotics, and supportive care, severe cases may still require diversion with an ostomy for the child's survival.

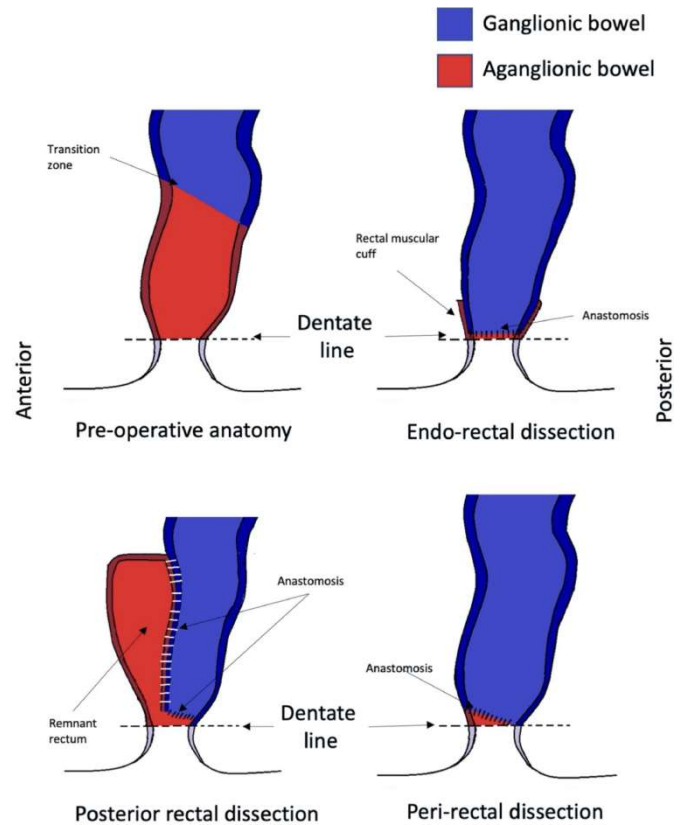


Figure 1.

Although a leveling colostomy is a safe and acceptable option for fecal diversion, if pathology is available to confirm the appropriate level, a diverting ileostomy leaves more surgical options open for future pull-through procedures as it does not interfere with the vascular supply of the distal intestine. Older children with Hirschsprung's disease often have severe intestinal dilation and fecal retention due to ongoing obstruction, preventing a one-stage procedure. These patients often have a component of malnutrition that will also put the anastomosis at risk for complications. Typically, these patients are initially treated with fecal diversion and a follow-up contrast enema several months later to assess intestinal caliber before the pull-through procedure is performed (SMITH, Caitlin, 2020). Other patients who may be primarily treated with diversion include those with aganglionosis extending into the small intestine (total colonic aganglionosis) and patients with significant comorbidities such as congenital heart disease. Any patient who has not received adequate enteral nutrition or cannot be decompressed with rectal irrigations should also be treated with a diversion ostomy before pull-through (SMITH, Caitlin, 2020). Several studies have compared outcomes between one-stage and two-stage surgical interventions. Teitelbaum et al. reported on 78 infants who successfully underwent primary endorectal pull-through at an average age of a few days. Compared to the two-stage surgical approach, the one-stage group had a higher postoperative enterocolitis rate (42% vs. 22%) and a lower rate of anastomotic dehiscence. Otherwise, the outcomes were similar between the two groups, and both achieved excellent long-term results. Langer et al. also reported the experience of children who underwent a one-stage transanal Soave pull-through. All patients in this multicenter series achieved excellent results. Additionally, Santos et al. compared 47 patients undergoing a two-stage procedure with 18 undergoing primary pull-through, finding no difference in complication rates between the two groups (SMITH, Caitlin, 2020).

Postoperative Complications: Despite innovations in surgical techniques and medical care, many patients continue to experience long-term ongoing issues after pull-through surgery, including fecal incontinence (FI; >8%–74%), constipation (9%–40%), and

Hirschsprung-associated enterocolitis (HAEC) (25%-37%) (SMITH, Caitlin, 2020).

Anastomotic Stenosis: Anastomotic stenosis mainly occurs when there is a low circular anastomosis as in the transanal endorectal pull-through (TERPT). Risk factors include ischemia, leakage, and anastomotic tension. Stenoses may be less frequent after Duhamel compared to TERPT, with reported occurrence rates of up to 10.6%. Calibrating the coloanal anastomosis two to three times after surgery is recommended. The Hegar size 12 is appropriate for babies up to 6 months. There is no evidence that anal dilation programs prevent stenosis or enterocolitis (KYRKLUND, Kristiina, 2020).

Enterocolitis: Enterocolitis is the most serious and frequent complication after pull-through surgery. Risk factors include a family history, long-segment disease, Down syndrome, and previous episodes of enterocolitis. Patients with explosive diarrhea, decreased peripheral perfusion, lethargy, and/or dilated intestinal loops on X-rays have severe HAEC. These patients should be treated with rectal washouts, fluid resuscitation, and intravenous metronidazole in the hospital. Washouts and oral antibiotics should be continued at home. In cases of recurrent HAEC, mechanical obstruction or residual aganglionosis should be ruled out. Contrast enemas should not be performed during an acute episode due to the risk of perforation (KYRKLUND, Kristiina, 2020). In a study by J. Hagens et al., 4,738 articles were identified, of which 57 studies were included, comprising 9,744 preoperative and 8,568 postoperative cases. The groups were categorized by the extent of the aganglionic segment for further analysis. The pooled prevalence for preoperative HAEC was 18.3% for all types, 15.2% for short-segment aganglionosis, and 26.1% for total colonic aganglionosis (TCA). The pooled prevalence for postoperative HAEC was 18.2% for all segment lengths and techniques used. Subgroup analysis did not show a significant difference in the occurrence of postoperative enterocolitis among the three techniques. It was concluded that the prevalence of preoperative HAEC increases with the segment length. However, the pooled data suggest that the postoperative risk for developing HAEC, regardless of the employed method and segment length, is comparable to the preoperative risk (HAGENS, 2021).

Fecal Incontinence: For fecal incontinence, contrast enemas are useful in differentiating between hypo- and hypermotility. Both hypo- and outlet obstruction can lead to overflow incontinence and colon dilation, and should be differentiated from hypermotility disorders as their treatment differs. Patients with intact dentate line and good sphincter function without outlet obstruction but with colonic hypomotility are managed with oral laxatives and enemas as needed. Patients with colonic hypermotility, often due to loss of rectal reservoir, need interventions to slow down transit. These include a constipating diet, loperamide, and bulk agents (pectin, psyllium). If the dentate line and/or sphincter musculature are significantly damaged, the management involves artificially emptying the colon. If medical interventions and bowel management fail, a permanent stoma may be the last resort (KYRKLUND, Kristiina, 2020).

Obstruction: Anastomotic stenosis, Duhamel spur, obstructed Soave muscle cuff, twisted pull-through or retained aganglionic pull-through or transition zone. Histology should be reviewed. Repeat colon transanal biopsy should be considered to confirm normal innervation of the pulled-through colon. For anastomotic stenoses, anal dilations may be attempted. If no cause of obstruction is found, the first-line treatment consists of intersphincteric botulinum toxin injections to relieve internal sphincter achalasia. If symptoms do not improve after >3 botulinum toxin injections, bowel management is the second-line treatment. Bowel management should be individualized based on patient preferences. Options include regular retrograde enemas or antegrade colonic irrigation (ACE) or cecostomy (CHAIT, button) in combination with oral laxatives and diet. Surgical reapproach should be considered in symptomatic patients with recalcitrant stenosis, twisted pull-through, rolled Soave muscle cuff, Duhamel spur, or aganglionic pull-through/transition zone (KYRKLUND, Kristiina, 2020). There are several strategies for postoperative assessment of the

pull-through anastomosis. In infants, the anastomosis can be sized by the passage of Hegar dilators in the clinic. If there is concern for stenosis or anastomotic stricture, the family can be taught to pass a dilator at home to prevent further narrowing of the anastomosis. An alternative method for anastomosis assessment is rectal examination under anesthesia around 30 days postoperatively. This can be performed alongside internal anal sphincter (IAS) botulinum toxin administration if there are concerns about ongoing obstructive-type symptoms with difficulty evacuating stools and the anastomosis is well healed and patent. Some institutions prophylactically administer IAS botulinum toxin injection at 1 month postoperatively. Overall, a rectal examination under anesthesia at 1 month postoperatively is recommended to determine which patients, if any, require postoperative dilations. Similarly, at our institution, a measured approach to intersphincteric botulinum toxin injection is adopted and reserved for patients with anastomosis evidence of no stenosis and continuous obstructive-type symptoms in the postoperative period [6]. A recent meta-analysis of two case-control studies by Soh et al. did not report a difference in postoperative stenosis incidence with routine dilations. Moreover, they reported decreased enterocolitis incidence with postoperative routine rectal irrigations implemented for a duration of 1 to 2 weeks or 10 days. However, prospective controlled studies are lacking (KAPUR, Raj, 2020).

Postoperative Complications: Despite advancements in surgical techniques and medical care, many patients still face ongoing long-term issues following pull-through surgery for Hirschsprung's disease, including fecal incontinence (FI; >8%-74%), constipation (9%-40%), and Hirschsprung-associated enterocolitis (HAEC) (25%-37%) (SMITH, Caitlin, 2020).

Anastomotic Stenosis: Anastomotic stenosis is commonly observed, particularly when a low circular anastomosis is performed, such as in transanal endorectal pull-through (TERPT). Risk factors for stenosis include ischemia, leakage, and anastomotic tension. The occurrence of stenosis might be lower after the Duhamel procedure compared to TERPT, with reported rates of up to 10.6%. To prevent stenosis, it is recommended to calibrate the coloanal anastomosis two to three times after surgery. For infants up to six months old, using a Hegar size 12 dilator is suitable. However, there is no evidence supporting the use of anal dilation programs to prevent stenosis or enterocolitis (KYRKLUND, Kristiina, 2020).

Enterocolitis: Enterocolitis remains the most serious and frequent complication following pull-through surgery. Risk factors for HAEC include a family history of the disease, extensive aganglionosis, Down syndrome, and previous episodes of enterocolitis. Severe HAEC is characterized by explosive diarrhea, decreased peripheral perfusion, lethargy, and/or dilated intestinal loops visible on X-rays. Patients with severe HAEC should be managed with rectal washouts, fluid resuscitation, and intravenous metronidazole in a hospital setting. This treatment is followed by at-home washouts and oral antibiotics. For cases of recurrent HAEC, mechanical obstruction or residual aganglionosis should be ruled out. During an acute episode, contrast enemas should be avoided due to the risk of perforation (KYRKLUND, Kristiina, 2020). A study conducted by J. Hagens et al. analyzed 4,738 articles, from which 57 studies were included, covering 9,744 preoperative and 8,568 postoperative cases. The groups were categorized based on the extent of aganglionic segments for further analysis. Pooled prevalence rates for preoperative HAEC were 18.3% for all types, 15.2% for short-segment aganglionosis, and 26.1% for total colonic aganglionosis (TCA). The pooled prevalence rate for postoperative HAEC was 18.2% across all segment lengths and techniques used. Subgroup analysis did not show a significant difference in the occurrence of postoperative enterocolitis among the three techniques. This led to the conclusion that the prevalence of preoperative HAEC increases with the length of the aganglionic segment. However, the pooled data suggests that the postoperative risk of developing HAEC, regardless of the surgical method or segment length used, is comparable to the preoperative risk (HAGENS, 2021).

Table 1

| | | | | |
|----------------------------|------|--|-----------------------------------|------------------------------|
| Yun-Ying Gong | 2022 | "Systematic Evaluation of Guidelines for Hirschsprung's Disease Management" | Systematic Review | |
| J Hagens et al. | 2022 | "Prevalence of Enterocolitis in Hirschsprung's Disease" | Systematic Review | 18312 patients 57 studies |
| Maggie L Westfal et al. | 2022 | "Optimal Timing for Primary Soave Procedure in Hirschsprung's Disease" | Metanalysis | 780 patients |
| Colin D. et al. | 2022 | "Management of Anorectal Malformations and Hirschsprung's Disease" | Systematic Review | |
| Benjamin S. R. Allinab | 2022 | "Impact of Endorectal Surgery on School-Age Patients" | Coorte study | 305 patients |
| Sanne J Verkuijl | 2021 | "Neuropathological Perspective of Persistent Intestinal Dysfunction after Hirschsprung's Surgery" | Systematic Review | |
| Kristina Kyrklund | 2020 | "Best Practices of the ERNICA Network for Hirschsprung's Disease" | Guideline | |
| Catlin Smith | 2020 | "Surgery, Pathological Analysis, and Postoperative Management of Hirschsprung's Disease" | Narrative review | |
| Raj P Kapur et al. | 2020 | "Postoperative Obstruction in Hirschsprung's Disease" | Narrative review | |
| Fan Mei et al. | 2020 | "Use of Probiotics in Preventing Hirschsprung's-Associated Enterocolitis" | Systematic Review | 122 patients |
| Lusine Ambartsumyan et al. | 2020 | "Diagnosis of Hirschsprung's Disease" | Systematic Review | |
| Bei Lei Yan et al. | 2019 | "Comparing Transanal Endorectal and Transabdominal Surgery in Hirschsprung's Disease" | Systematic Review and Metanalysis | 724 patients 87 studies |
| Raj P Kapur | 2019 | "Diagnostic Challenges in Hirschsprung's Disease" | Narrative review | |
| Yong-Zhong Mao et al. | 2018 | "Comparison of Duhamel Procedure with Transanal Endorectal Surgery" | Systematic Review and Metanalysis | 280 patients 6 studies |
| Shogo Seo et al. | 2018 | "Comparing Duhamel Procedure and Transanal Endorectal Surgery in Hirschsprung's Disease Treatment" | Systematic Review and Metanalysis | 430 patients 7 studies |

Fecal Incontinence: Contrast enemas are valuable for distinguishing between hypo- and hypermotility in cases of fecal incontinence. Both hypo- and outlet obstruction can lead to overflow incontinence and colon dilation, requiring differentiation from hypermotility disorders due to distinct treatment approaches. Patients with an intact dentate line and satisfactory sphincter function but no outlet obstruction, and suffering from colonic hypomotility, can be managed with oral laxatives and enemas as needed. Conversely, patients experiencing colonic hypermotility, often due to the loss of the rectal reservoir, require interventions to slow down transit. Such interventions may involve a constipating diet, loperamide, and bulk agents like pectin or psyllium. In cases of significant damage to the dentate line and/or sphincter musculature, managing the emptying of the colon through artificial means becomes necessary. Should medical interventions and bowel management prove ineffective, a permanent stoma might be the final option (KYRKLUND, Kristiina, 2020).

Obstruction: Obstruction can occur due to various reasons such as anastomotic stenosis, Duhamel spur, obstructed Soave muscle cuff, twisted pull-through, or retained aganglionic pull-through or transition zone. Histological review is essential. Consideration should be given to repeat colon transanal biopsies to confirm the normal innervation of the pulled-through colon. In the case of anastomotic stenosis, anal dilatations may be attempted. If no identifiable cause of obstruction is found, the initial treatment consists of intersphincteric botulinum toxin injections to alleviate internal sphincter achalasia. If symptoms persist after >3 botulinum toxin injections, the second-line treatment is bowel management. The approach to bowel management should be tailored to individual patient preferences, which may include regular retrograde enemas, antegrade colonic irrigation (ACE), or cecostomy (CHAIT, button) combined with oral laxatives and dietary adjustments. For symptomatic patients with recalcitrant stenosis, twisted pull-through, rolled Soave muscle cuff, Duhamel spur, or aganglionic pull-through/transition zone, surgical re-intervention should be considered (KYRKLUND, Kristiina, 2020). Several strategies are available for postoperative assessment of the pull-through anastomosis. In infants, Hegar dilators can be used to size the anastomosis during clinic visits. Families can be educated to use dilators at home if there is concern about stenosis or anastomotic stricture to prevent further narrowing of the anastomosis. Another approach for anastomosis assessment involves performing a rectal examination under anesthesia around 30 days postoperatively. This can be coupled with the administration of botulinum toxin to the internal anal sphincter (IAS) if ongoing obstructive-type symptoms with difficulty evacuating stools persist and the anastomosis is well-healed and patent. In some institutions, prophylactic administration of IAS botulinum toxin injections at 1 month postoperatively is considered.

Overall, a rectal examination under anesthesia at 1 month postoperatively is recommended to determine which patients, if any, require postoperative dilations. Similarly, at our institution, a measured approach to intersphincteric botulinum toxin injection is adopted and reserved for patients with anastomosis evidence of no stenosis and continuous obstructive-type symptoms in the postoperative period (SMITH, Caitlin, 2020). A recent meta-analysis of two case-control studies by Soh et al. did not report a difference in postoperative stenosis incidence with routine dilations. Moreover, they reported decreased enterocolitis incidence with postoperative routine rectal irrigations implemented for a duration of 1 to 2 weeks or 10 days. However, prospective controlled studies are lacking (KAPUR, Raj, 2020).

CONCLUSION

Hirschsprung's Disease (HD) is a genetic anomaly characterized by the absence of ganglion cells in the intestine, leading to functional intestinal obstruction. The initial diagnosis is based on clinical symptoms, and confirmation is achieved through biopsies of aganglionic segments (considered the gold standard). Other auxiliary tests such as anorectal manometry and contrast enema are also useful. The treatment involves removing the affected segment of the colon, pulling the healthy intestinal segment towards the anus, and preserving the function of the anal sphincter. There are different surgical approaches, with the transanal endorectal pull-through (TERPT) and transabdominal (TAB) being the most common. Procedures like Duhamel and endorectal pull-through are most frequently performed today. When comparing TERPT and Duhamel, the endorectal technique has a shorter hospital stay and lower incidence of constipation, while the Duhamel technique is associated with a lower rate of complications such as enterocolitis and anastomotic stenosis. However, there is no consensus on factors such as surgery duration and fecal incontinence rate. When comparing the three transabdominal techniques, the Swenson procedure showed a higher need for reoperation, while the Duhamel procedure demonstrated a lower incidence of fecal incontinence, albeit with a higher rate of constipation between ages 5 and 8. Nonetheless, there are still many randomized studies that need to be evaluated, and it is expected that more clinical trials will be conducted in the future. Complications after HD surgery include obstruction, fecal incontinence, enterocolitis, and dermatitis. Clinical approaches such as serial dilations, the use of probiotics, and botulinum toxin injections have not demonstrated statistically significant benefits thus far. The management of intestinal issues is complex, but with early interventions and ongoing care, it is possible to provide a good quality of life for these children.

REFERENCES

- ALLIN, Benjamin SR et al. Impact of rectal dissection technique on primary-school-age outcomes for a British and Irish cohort of children with Hirschsprung disease. *Journal of Pediatric Surgery*, v. 57, n. 12, p. 902-911, 2022.
- AMBARTSUMYAN, Lusine; SMITH, Caitlin; KAPUR, Raj P. Diagnosis of Hirschsprung disease. *Pediatric and Developmental Pathology*, v. 23, n. 1, p. 8-22, 2020.
- GAUSE, Colin D.; KRISHNASWAMI, Sanjay. Management of Anorectal Malformations and Hirschsprung Disease. *Surgical Clinics*, v. 102, n. 5, p. 695-714, 2022.
- GONG, Yun-Ying et al. Systematic appraisal of the guidelines for the diagnosis and treatment of Hirschsprung's disease. *Pediatric Surgery International*, p. 1-12, 2022.
- HAGENS, J.; REINSHAGEN, K.; TOMUSCHAT, C. Prevalence of Hirschsprung-associated enterocolitis in patients with Hirschsprung disease. *Pediatric Surgery International*, p. 1-22, 2021.
- KAPUR, Raj P.; AMBARTSUMYAN, Lusine; SMITH, Caitlin. Are we underdiagnosing Hirschsprung disease?. *Pediatric and Developmental Pathology*, v. 23, n. 1, p. 60-71, 2020.
- KAPUR, Raj P.; SMITH, Caitlin; AMBARTSUMYAN, Lusine. Postoperative pullthrough obstruction in Hirschsprung disease: etiologies and diagnosis. *Pediatric and Developmental Pathology*, v. 23, n. 1, p. 40-59, 2020.
- KYRKLUND, Kristiina et al. ERNICA guidelines for the management of rectosigmoid Hirschsprung's disease. *Orphanet Journal of Rare Diseases*, v. 15, n. 1, p. 1-16, 2020.
- MAO, Yong-zhong; TANG, Shao-tao; LI, Shuai. Duhamel operation vs. transanal endorectal pull-through procedure for Hirschsprung disease: A systematic review and meta-analysis. *Journal of pediatric surgery*, v. 53, n. 9, p. 1710-1715, 2018.
- MEI, Fan et al. Probiotics for the prevention of Hirschsprung-associated enterocolitis. *Cochrane Database of Systematic Reviews*, n. 4, 2022.
- SEO, Shogo et al. Duhamel and transanal endorectal pull-throughs for Hirschsprung'disease: a systematic review and meta-analysis. *European Journal of Pediatric Surgery*, v. 28, n. 01, p. 081-088, 2018.
- SMITH, Caitlin; AMBARTSUMYAN, Lusine; KAPUR, Raj P. Surgery, surgical pathology, and postoperative management of patients with Hirschsprung disease. *Pediatric and Developmental Pathology*, v. 23, n. 1, p. 23-39, 2020.
- VERKUIJL, Sanne J. et al. Persistent bowel dysfunction after surgery for Hirschsprung's disease: A neuropathological perspective. *World Journal of Gastrointestinal Surgery*, v. 13, n. 8, p. 822, 2021.
- WESTFAL, Maggie L. et al. Optimal timing for Soave primary pull-through in short-segment Hirschsprung disease: A meta-analysis. *Journal of Pediatric Surgery*, v. 57, n. 4, p. 719-725, 2022.
- YAN, Bei-lei et al. Transanal endorectal pull-through procedure versus transabdominal surgery for Hirschsprung disease: a systematic review and meta-analysis. *Medicine*, v. 98, n. 32, 2019.
