



ISSN: 2230-9926

Available online at <http://www.journalijdr.com>

# IJDR

International Journal of Development Research

Vol. 14, Issue, 03, pp. 65118-65121, March, 2024

<https://doi.org/10.37118/ijdr.27968.03.2024>



RESEARCH ARTICLE

OPEN ACCESS

## BURGESS TECHNIQUE VS MODIFIED BRUCKNER PROCEDURE IN BELOW KNEE AMPUTATION -A PROSPECTIVE RANDOMISED CONTROL STUDY

\*Dr. Jayalal, J.A., Dr. Selwyn J Kumar, Dr. P. Ram Praveen, Dr. Geolin Mithun and Dr. Keerthana Baskar

Professor and HOD of General Surgery, Kanyakumari Govt. Medical College

### ARTICLE INFO

#### Article History:

Received 02<sup>nd</sup> January, 2024

Received in revised form

17<sup>th</sup> January, 2024

Accepted 16<sup>th</sup> February, 2024

Published online 27<sup>th</sup> March, 2024

#### Key Words:

Burgess technique, Below knee amputation, Bruckner technique, Stump revision.

### ABSTRACT

Below knee amputation is most commonly performed in peripheral vascular disease and diabetes mellitus and in more than 50% of the cases diabetic foot infection forms the sole indication of lower limb amputation. Long posterior flap technique of burgess for below knee amputation has been commonly used since 1960s, modification of long posterior flap technique of burgess, medial-lateral sagittal flap technique, medial dominant sagittal flap technique also exist in the literature. However, none of these techniques have proven to be superior to long posterior flap technique of burgess. But in the burgess technique, assessment of viability of the crural muscles relies upon the experience of the surgeon, thus problems of wound healing and secondary procedures due to muscle necrosis are frequently encountered. Because of these disadvantages, lutz Bruckner has modified the burgess technique and described his own modification where muscles of anterior and lateral compartments, together with the soleus muscle and if necessary the fibula, are removed to avoid secondary procedures due to muscle necrosis and tension in the stump. In this study, in this study we will study about the outcomes of Burgess technique vs modified Bruckner procedure. **Materials and Methods:** This study comprises of population of 50 patients admitted who has underwent Below Knee amputation in Kanyakumari Government Medical College Hospital. The patients enrolled for the study will be randomly categorised in to two groups with one group undergoing burgess technique and other modified Bruckner technique. Informed written consent will be obtained from all patients. The primary outcomes such wound infection, flap necrosis, need for revision surgery, length of hospital stay, functional rehabilitation will be compared in these techniques. **Results:** In this study, the mean age of the patient is 67.2(38-71) in 32 males and 28 females. Stump revision is needed in 4 patients (17.1%) who underwent burgess technique and in only one patient who underwent modified Bruckner technique. Flap necrosis was seen in 47% of patients in burgess technique and of 16% in modified Bruckner technique. The average length of hospital stay is 21.5 days and 14.96 days in burgess and Bruckner technique respectively. Mortality is seen in 12% and 4% in burgess and Bruckner technique respectively. **Conclusion:** Individuals having below-knee amputation utilising either of the two processes in this study demonstrated that those using the modified Bruckner approach had a higher rate of primary wound healing and a better outcome than those using the regular Burgess technique.

\*Corresponding author: Dr. Jayalal,

Copyright©2024, Bianca Couto. This is an open access article distributed under the Creative Commons Attribution License, which permits unrestricted use, distribution, and reproduction in any medium, provided the original work is properly cited.

Citation: Dr. Jayalal, J.A., Dr. Selwyn J Kumar, Dr. P. Ram Praveen, Dr. Geolin Mithun and Dr. Keerthana Baskar, 2024. "Uso dos chás durante a gravidez e suas implicações". International Journal of Development Research, 14, (02), 65118-65121.

## INTRODUCTION

A below-knee amputation (BKA), is a transtibial amputation in which the foot, ankle joint, distal tibia, fibula, and related soft tissue components are removed. Amputation of the lower extremities is a life-saving treatment. Lower limb ischemia, peripheral artery disease, and diabetes are thought to be the leading causes of limb amputations in more than half of all instances. Amputations below the knee are connected with better functional results than amputations above the knee. This surgical procedure has high morbidity, but it is nonetheless a therapy technique with critical clinical and often life-saving implications when used appropriately. Ernest M. Burgess was the first to describe the extraordinary functional influence on transtibial zone preservation. The level of amputation should be as distal as feasible as a general rule, with the primary goal of preserving the knee.

Burgess and Zettl described a lengthy posterior myocutaneous flap surgical method for excellent soft tissue regeneration of the residual limb following BKA in the late 1960s. Since then, the Burgess approach has become known as the "gold standard" for soft tissue covering in BKA. But numerous studies on sagittal flap technique, modification of long posterior flap technique of Burgess, medial-lateral sagittal flap technique, medial dominant sagittal flap technique also exist in the literature. However, none of these techniques have proven to be superior to long posterior flap technique of Burgess. But in the Burgess technique, assessment of viability of the crural muscles relies upon the experience of the surgeon, thus problems of wound healing and secondary procedures due to muscle necrosis are frequently encountered. Because of these drawbacks, Lutz Bruckner modified the Burgess technique and described his own modification in which muscles of the anterior and lateral compartments, as well as the soleus muscle and, if necessary, the fibula, are removed to avoid

secondary procedures due to muscle necrosis and stump tension. In this study, we describe a novel technique derived from the Burgess technique and analyse the results of TTAs performed with this technique in hindsight; we also compare these two techniques.

## MATERIALS AND METHODS

**Study Population:** Patients who are undergoing BK amputation in our department of general surgery in Kanyakumari medical college.

**Study Design:** Randomised control trial.

**Study Period:** 6 Months.

**Sample Size:** It is a hospital based study with 25 patients undergoing burgess technique and 25 patients undergoing modified Bruckner technique.

### Inclusion Criteria

- 1) Age above 25 years and less than 75 Years
- 2) All patients undergoing BK amputation except traumatic cause

### Exclusion Criteria

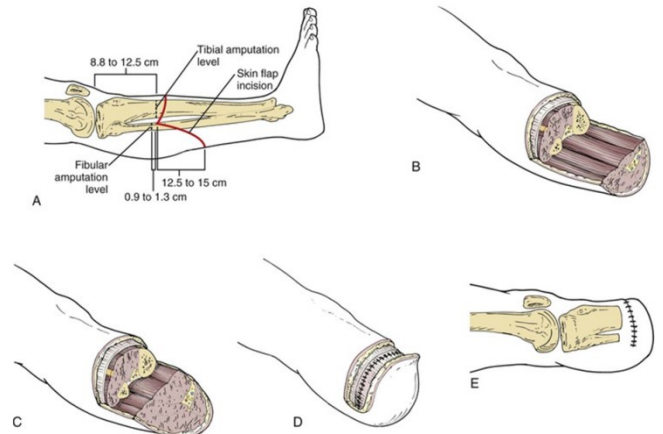
- 1) Traumatic amputation
- 2) Guillotine amputation

The patients enrolled for the study will be randomly categorised in to two groups with one group undergoing burgess technique and other modified Bruckner technique. Informed written consent will be obtained from all patients. Both the groups of patients are treated with antibiotics according to wound culture and sensitivity, daily cleaning and dressing, adequate pain relief and co-morbidity correction. The wound was opened on POD -1. The primary outcomes such wound infection, flap necrosis, need for revision surgery, length of hospital stay, functional rehabilitation will be compared in these techniques.

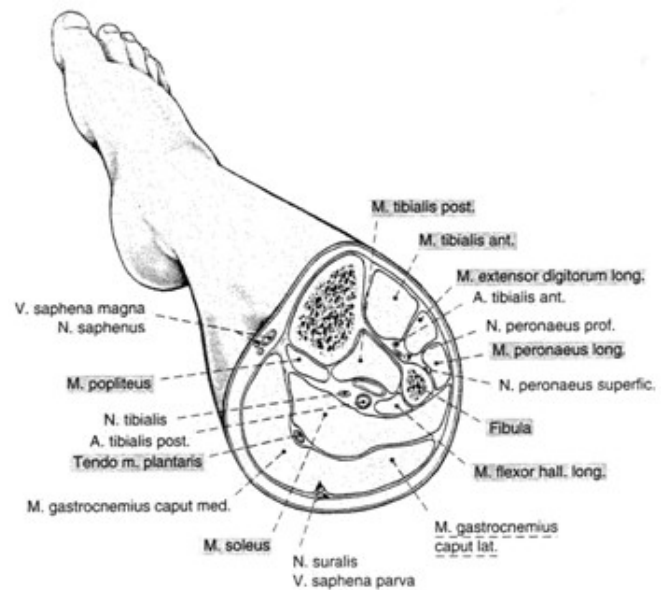### Surgical Techniques:

**Burgess Technique:** The tibiofemoral joint line is located in the middle of the patellar tendon. A line is drawn 15 cm distal to the joint line, corresponding to the tibial resection level and the appropriate residual limb length for perfect prosthetic fitting and rehabilitation. The dorsal myocutaneous flap has an extra length of about 10-15 cm, which corresponds to the junction of the proximal two-thirds and distal one-third of the anteroposterior aspect of the lower leg (i.e. around 25-30 cm distal to the joint line). As a general guideline, the posterior flap should be 5 cm longer than the calf diameter at the level of the anterior incision. A recent study advised rounding up the perpendicular incision with a quarter-sized circle to eliminate 'dog ears' at the intersection of the anterior and posterior resection margins. The incision is carried down into the skin, subcutaneous tissue, and fascia, dividing the muscle compartments. Full-thickness flaps are created with care to avoid compromising the subcutaneous tissues, thus Keeping dead space and ischemic skin margins at bay. The tibial cut is made using a Gigli or oscillating saw 10-12 cm below the joint line. The anterior edge of the tibia is bevelled by approximately 45° after the initial perpendicular tibial incision, and the edges are softened to eliminate harsh margins. The fibula is cut 10-15 mm shorter than the tibia, with the edges flattened. With an amputation knife, the fascia of the deep posterior compartment is dissected from the rear of the tibia and fibula. To finish the amputation, the dissection is carried down distally to the previously established incision lines. All important peripheral nerves are recognised and separated from the soft tissue. After a 0.5% bupivacaine infiltration, the nerves are gently retracted as far distal as feasible, ligated, and transected in their most apparent aspect. This movement causes the nerve endings to retract proximally into the soft tissue, reducing the chance of a symptomatic neuroma caused by mechanical compression.

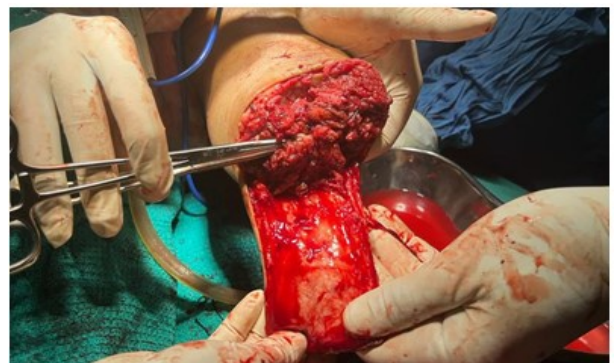Non-absorbable suture is used to ligature the arteries and veins. To avoid a large flap that can interfere with prosthesis fitting, the posterior flap is prepared by debulking the soleus muscle as needed. Before wound closure, meticulous haemostasis is accomplished. After placing deep drains, the flap is rotated anteriorly and secured with a fascioperiosteal suture. To avoid local skin necrosis, the skin boundaries must be managed cautiously, and the skin suture is positioned anteriorly to the stump. This method of closure ensures that the scar is outside the weight-bearing region of the myocutaneous flap.



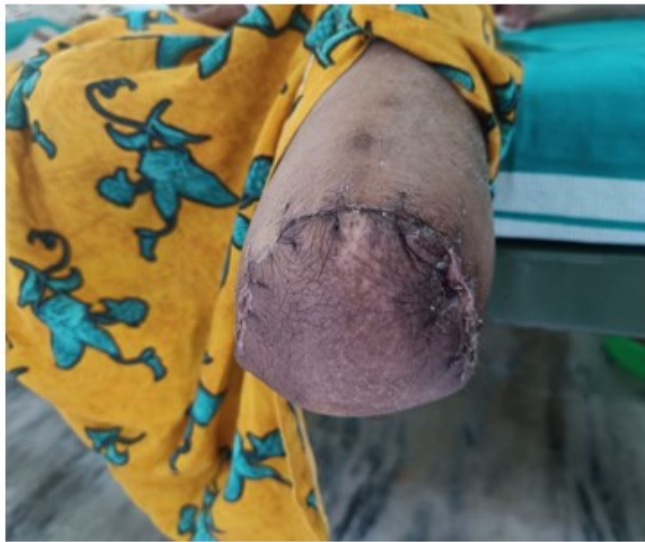**Burgess technique. A, Marking the skin incisions. B, Fashioning the flaps after bone transection. C, The soleus muscle is tailored to create a proper flap. D, The posterior deep fascia is sutured to the anterior deep fascia and periosteum. E, Closure of skin flaps**



**Cross section of the proximal part of the lower leg**



**After the removal of soleus**



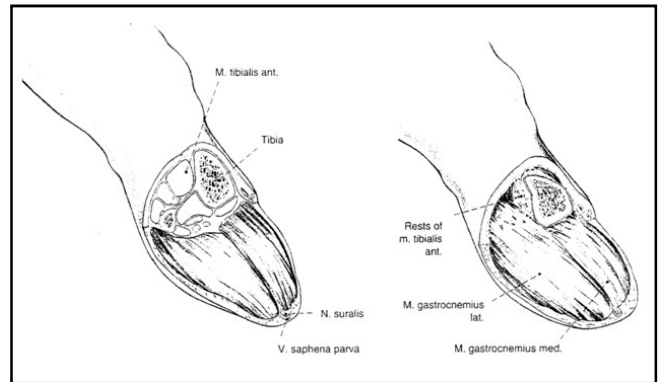
Stump 15 days after BK amputation by Bruckner's technique

**Modified Bruckner Technique:** The landmarks and skin incision placement are identical to the Burgess procedure. The tibia is transected and prepared in the same way, but the fibula is disarticulated proximally and completely resected, with the goal of avoiding a delayed abduction deformity due to the absence of the interosseus membrane, especially when the tibia must be resected 2 cm below the tuberosity. The total excision of the front and lateral compartments differs significantly from the Burgess approach. Furthermore, the soleus muscle is entirely removed. The posterior myocutaneous flap is mostly composed of the medial gastrocnemius, with parts of the lateral gastrocnemius maintained only when the medial portion alone is insufficient for an acceptable soft tissue flap. A deep drain is installed in the previous fibular compartment, and the stump is closed using the Burgess technique.

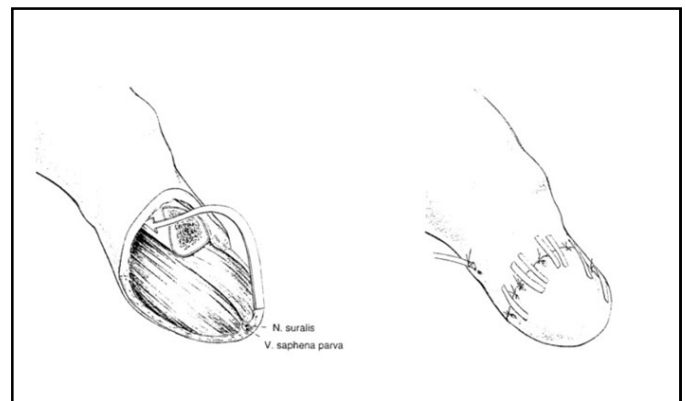
## DISCUSSION

Ernest M. Burgess' approach attempted to create a stump covered by a long posterior myocutaneous flap to minimise anterior soft tissue necrosis, which was a common complication of BKA treatments in the "pre-Burgess era." Since its inception, the Burgess flap has been regarded as the "gold standard" for transtibial amputations. One major concern with the Burgess approach in patients with stage IV peripheral occlusive artery disease is the requirement for a subjective intraoperative assessment of muscle vitality based on tissue colour, micro perfusion, and muscular contractility. This clinical assessment is heavily reliant on the surgeon's own expertise and may be difficult to perform in important individual instances. Thus, the postoperative complication rate in this high-risk population is significant in terms of wound healing issues, soft tissue necrosis, and infection. Lutz Bruckner's rationale for changing the traditional Burgess technique was to reduce the need for subjective assessment of tissue quality by adopting a more systematic procedure that is independent of individual viewpoint. In basic research studies, Bruckner showed that the muscles of the lower leg have a clearly distinct 'biological value' with regard to clinical, histomorphometric and biochemical analyses.<sup>37-39</sup> In this regard, Bruckner showed that the medial gastrocnemius has the highest ischaemic tolerance of all lower leg muscles, whereas the tibialis anterior is the muscle with the highest susceptibility to ischaemic insult.<sup>37-39</sup> These findings have been confirmed by others. McCollum et al. found that the muscles on the medial side of the calf, in patients with occlusive arterial disease, have an increased perfusion, compared to the lateral musculature. Furthermore, Grey and Ng demonstrated that in individuals with occlusive vascular disease, the soleus muscle does not contribute to the perfusion of the posterior myocutaneous flap. Because the extensive venous plexus of the soleus muscle is at danger of thrombosis due to a relative stasis caused when the flap is anteriorly rotated, it should be entirely removed.

When a high resection of the tibia (2 cm below the tuberosity) is required, full disarticulation of the fibula results in a stump, allowing for quicker weight bearing. Complete excision of the fibula relieves soft tissue strain produced by abduction malposition of the proximal fibula due to the absence of the interosseus membrane. Overall, this improved treatment reduces the risk of postoperative soft tissue problems.



Operative site after the removal of the distal segment. The soleus, fibula is also removed



Closure of skin flaps

## RESULTS

In this study, Flap necrosis was seen in 47% (n=11) of the patients who underwent Burgess technique and in 16% (n=4) of patients who underwent modified Bruckner procedures. Stump revision was done in 4 cases in Burgess technique whereas only one case undergoes stump revision in modified Bruckner technique. The rate of wound healing by primary intention is 44.6% in Burgess technique whereas it is 79.3% in modified Bruckner technique. The wound healing by secondary intention is 29.2% and in modified Bruckner technique it is 12.4%. The mortality is 12% in Burgess technique and 4% in modified Bruckner technique. The average length of hospital stay is 21.5 days in Burgess technique and 14.9 days in modified Bruckner technique.

	BURGESS TECHNIQUE	MODIFIED BRUCKNER TECHNIQUE
Flap necrosis	47%(11/25)	16%(4/25)
Stump revision	17.1%(4/25)	3.2%(1/25)
Rate of wound healing per primum	44.6%(11/25)	79.3%(20/25)
Rate of wound healing per secundum	29.2%(7/25)	12.4%(3/25)
Length of hospital stay	21.5 days	14.9 days
Mortality	12%(3/25)	4%(1/25)

In cases involving the Burgess technique, repeated revision surgeries as a result of issues with the stump's incision site and muscle necrosis

have lengthened hospital stays, postponed rehabilitation, decreased the functionality of the prosthesis due to the shortened stump, and worsened patients' psychological conditions. The published work's longitudinal research on the Bruckner process are consistent with our own observations. The modified Bruckner approach for transtibial amputations appears to be a viable option for this challenging subset of patients due to the decreased rate of soft tissue problems and positive functional rehabilitation outcomes. When comparing published data on the Burgess versus Bruckner technique, the capacity to preserve the knee articulation, which is a vital prerequisite for a good functional result, is in a similar range.

## CONCLUSION

The 'traditional' Burgess approach for below knee amputation with a lengthy posterior myocutaneous flap was modified by Bruckner to be more consistent and direct. The 'biological viability' of the various muscles in the lower extremities is the foundation of this method. Except for the medial and lateral gastrocnemius, which make up the modified posterior flap, all of the calf muscles are entirely removed. Additionally, the entire proximal fibula has been removed. This standardised procedure enables a full-weight-bearing soft tissue stump following below knee amputation and is independent of the individual surgeons' assessment of muscle viability. According to the data presented in this paper on 50 patients who underwent BK amputation using either of the two procedures, patients who underwent the modified Bruckner technique had a higher rate of primary wound healing and a better outcome in terms of functional rehabilitation. The Bruckner procedure represents a comparable option to the "classical" long posterior Burgess flap for patients receiving Below knee amputation.

## REFERENCES

Baumgartner R. Unterschenkelamputation [Transtibial amputation]. *Oper Orthop Traumatol*. 2011 Oct; 23(4):280-8. German. doi: 10.1007/s00064-011-0040-z. PMID: 21922230.

- Boucher F, Ho Quoc C, Pinatel B, Thiney PO, Mojallal A. Sauvetage d'un moignon d'amputation transtibiale grâce à un lambeau cutané basé sur les perforantes de l'artère tibiale postérieure [Transtibial amputation salvage with a cutaneous flap based on posterior tibial perforators]. *Ann Chir Plast Esthet*. 2013 Aug;58(4):342-6. French. doi: 10.1016/j.anplas.2012.08.004. Epub 2012 Oct 25. PMID: 23102914.
- Brückner, L. The Brückner standardized below knee amputation procedure following chronic occlusive arterial disease. *Orthop. Traumatol*. 2, 36-43 (1993). <https://doi.org/10.1007/BF02620534>
- Jesani L, Gwilym B, Germain S, Jesani H, Stimpson A, Lennon A, Massey I, Twine CP, Bosanquet DC. Early and Long Term Outcomes Following Long Posterior Flap vs. Skew Flap for Below Knee Amputations. *Eur J Vasc Endovasc Surg*. 2020 Aug;60(2):301-308. doi: 10.1016/j.ejvs.2020.03.049. Epub 2020 Apr 24. PMID: 32336620.
- Jones RF. Surgical technique. Concepts of transtibial amputation: Burgess technique versus modified Bruckner procedure. *ANZ J Surg*. 2007 Apr;77(4):307. doi: 10.1111/j.1445-2197.2007.04046.x. PMID: 17388846.
- Stahel PF, Oberholzer A, Morgan SJ, Heyde CE. Concepts of transtibial amputation: Burgess technique versus modified Brückner procedure. *ANZ J Surg*. 2006 Oct;76(10):942-6. doi: 10.1111/j.1445-2197.2006.03902.x. PMID: 17007627.
- Yurttas Y, Kürklü M, Demiralp B, Atesalp AS. A novel technique for transtibial amputation in chronic occlusive arterial disease: Modified Burgess procedure. *Prosthet Orthot Int*. 2009 Mar;33(1):25-32. doi: 10.1080/03093640802482559. PMID: 19235063.

\*\*\*\*\*