



## Full Length Research Article

### GYNECOMASTIA IN CHILDHOOD AND ADOLESCENCE: AT A GLANCE

\*<sup>1</sup>Amal A.AL-Hakami, <sup>2</sup>Rushaid N.A AL-Jurayyan and <sup>1</sup>Nasir A.M. Al Jurayyan,

<sup>1</sup>Departments of Pediatrics, College of Medicine and King Khalid University Hospital, King Saud University, Riyadh, Saudi Arabia

<sup>2</sup>Department of Radiology and Medical Imaging, College of Medicine and King Khalid University Hospital, King Saud University, Riyadh, Saudi Arabia

#### ARTICLE INFO

##### Article History:

Received 27<sup>th</sup> July, 2016  
Received in revised form  
14<sup>th</sup> August, 2016  
Accepted 19<sup>th</sup> September, 2016  
Published online 31<sup>st</sup> October, 2016

##### Key Words:

Adolescence, Childhood,  
Diagnosis, Gynecomastia,  
Pathogenesis, Therapy.

#### ABSTRACT

Gynecomastia, defined as a benign proliferative of the male's breast glandular tissue, is a common finding in boys during childhood and adolescence, and usually caused by increased estrogen activity, decreased testosterone activity, or the use of numerous medications. Although most cases are benign and self-limiting, it may represent signs of an underlying systemic diseases, drug induced or even male breast cancer. Understanding its pathogenesis is crucial to distinguish normal developmental variant from pathological causes. A stepwise approach that includes clinical assessment, imaging and laboratory testing to exclude neoplasia and endocrinopathies may facilitate cost effective diagnosis. This review will highlight the pathophysiology, etiology, diagnosis and the various medical and surgical therapies.

Copyright©2016, Amal A.AL-Hakami et al. This is an open access article distributed under the Creative Commons Attribution License, which permits unrestricted use, distribution, and reproduction in any medium, provided the original work is properly cited.

#### INTRODUCTION

Gynecomastia, defined as benign proliferation of the male's breast glandular tissue (Figure 1), a common finding in boys during childhood and adolescence, reported to be between 30 % and 60%. Most cases of gynecomastia in children occurs in the neonatal period, due to placental transfer of estrogen, and in puberty due to an imbalance between estrogens and androgens in breast. Although pre-pubertal gynecomastia is rare, and the majority are idiopathic. However there are various recognized causes including chronic diseases such as liver, renal or thyroid disorders. In addition, drugs have been associate with development of gynecomastia (Glenn and Braunstein 2007; Jurayyan 2016; Cuhaci et al 2014; Dickson 2012; Nordt and DiVasta 2008). In this brief review we highlight different aspects of male's breast enlargement in childhood particularly the pathophysiology, etiology, diagnosis and differential diagnosis and to discuss the different modalities of therapy.

#### Pathophysiology

The mechanism and pathophysiology of gynecomastia is not really clear. It is believed to be an altered imbalance between estrogen and androgen effects, absolute increase in estrogen effects either an increase in estrogen production, relative decrease in androgen production, or a combination of both. Estrogen acts as a growth hormone of the breast and, therefore, excess of estradiol in men leads to breast enlargement by inducing ductal epithelial hyperplasia, duct elongation and branching, and the proliferation of periductal fibroblasts and vascularity. Local tissue factors in the breast can also be important, for example, increased aromatic activity that can cause excessive local production of estrogen, decreased estrogen degradation and changes in the levels or activity of estrogen, and androgen receptors. Although prolactin (PRL) receptors are present in the male breast tissue, hyperprolactinemia may lead to gynecomastia through effects on the hypothalamic causing central hypogonadism. Activation of PRL, also, leads to decreased androgens and increased estrogen and progesterone receptors. The role of the hormones such as PRL, progesterone are well known. However, other growth factors such as insulin like growth factors (IGF-1) and epidermal growth factor (EGF), in the

\*Corresponding author: Amal A.AL-Hakami

Departments of Pediatrics, College of Medicine and King Khalid University Hospital, King Saud University, Riyadh, Saudi Arabia

development of gynecomastia need to be clarified (Wollina and Goldman 2011; Nuttall 2010). The spectrum of gynecomastia severity has been categorized into a grading system (Wollina and Goldman 2011):

#### Simon *et al* in (1973) proposed this grading system

- Grade I** Minor enlargement, no skin excess  
**Grade IIa** Moderate enlargement, no skin excess  
**Grade IIb** Moderate enlargement, minor skin excess  
**Grade III** Marked enlargement, skin excess (mimicking female breast)

#### Also, Rohrich *et al* have proposed a similar classification of gynecomastia:

- Grade I:** Minimal hypertrophy (<250 g), without ptosis  
**Grade II:** Moderate hypertrophy (259-500g) without ptosis  
**Grade III:** Severe hypertrophy (>500 g) with grade 1 ptosis  
**Grade IV:** Severe hypertrophy with grade II or III ptosis

#### Etiology of gynecomastia

Several etiological causes can lead to gynecomastia (table1) (Lanfranco *et al* 2004; Handelsman and Dong 1993; Karagiannis and Harsoulis 2005; Fentiman *et al* 2006; Deepinder and Braustein 2012 and Basaria 2010).

They can be classified into:

#### Physiological

Estrogen levels rise during neonatal and pubertal period, which leads to an elevated estrogen/testosterone ration and, hence, gynecomastia. The condition usually regresses within two years of onset.

#### Pathological

Gynecomastia can occur at any age, as a result of a number of medical conditions such as liver cirrhosis, primary hypogonadism and trauma.

#### Drug-induced

Medication induced gynecomastia is the most common cause. Agents associated with gynecomastia are listed in Table 2.

#### Differential diagnosis

The differential diagnosis of palpable breast mass in male patient includes pseudogynecomastia, gynecomastia, breast cancer and many other benign conditions. A review of all mammographic findings for men for a period of 5 years at Mayo Clinic, revealed a 1 % rate of malignancy. Most causes were due to benign conditions, of these, gynecomastia represented 62 % with other causes including lipomas, dermoid cyst, sebaceous cysts, lymphoplasmocystic inflammation, ductal ectasia, hematoma and fat necrosis.

#### Diagnosis of Gynecomastia

The history and physical examination should direct the laboratory and radiological imaging studies (Figures 3 and 4).

#### Clinical Evaluation: (History and physical examinations)

All boys with gynecomastia should be evaluated thoroughly by an experienced clinician. A detailed history should include the onset and duration of the breast enlargement, pain or tenderness, weight loss or gain, nipple discharge, virilization, medication history, and family history of gynecomastia which may suggest androgen insensitivity syndrome, familial aromatase excess or Sertoli cell tumors. Physical examination should differentiate between true gynecomastia and pseudogynecomastia (Figure 5) and should include signs of tumors, liver and kidney diseases, or hyperthyroidism and should also include genital examination. (Jurayyan 2016, Biro 1990; Hassan 2000; Cuhaci *et al* 2014; Dickson 2012; Gikas and Mokber 2007; Carlson 2011 and Derkacz 2011).

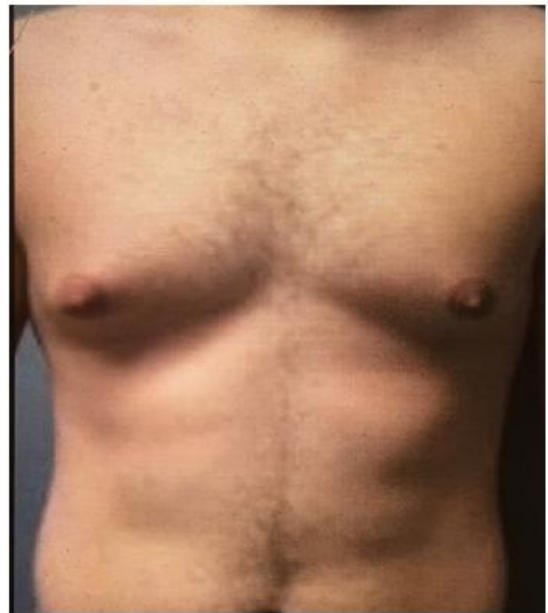


Figure 1. A 16 year old boy with gynecomastia

<b>Increase in estrogens</b>
Direct secretion (from testes/adrenals/placenta)
Extraglandular aromatisation of precursors
Decreased metabolism
Exogenous administration
<b>Decrease in endogenous free androgens</b>
Decreased secretion
Increased metabolism
Increased binding to sex hormone-binding globulin
<b>Altered serum androgen/estrogen ratio</b>
Puberty, aging, refeeding gynecomastia, hepatic cirrhosis,
Hyperthyroidism, drugs, renal failure and dialysis
<b>Androgen receptor defects</b>
<b>Enhanced sensitivity of breast tissue ?</b>

Figure 2. Pathophysiological mechanisms leading to gynecomastia

**Diagnostic Testing:** In cases without a clear cause, laboratory investigations should be pursued and must include liver, kidney and thyroid function tests as well as hormonal tests, estrogen, and free testosterone, luteinizing hormone (LH), follicle-stimulating hormone (FSH), prolactin, human chorionic gonadotrophin (HCG), dehydro epiandrosterone sulphate (DHEA-SO<sub>4</sub>) and Feto protein (FP). If testes are small the patient's karyotype should be obtained to rule out Klinefelter's Syndrome.

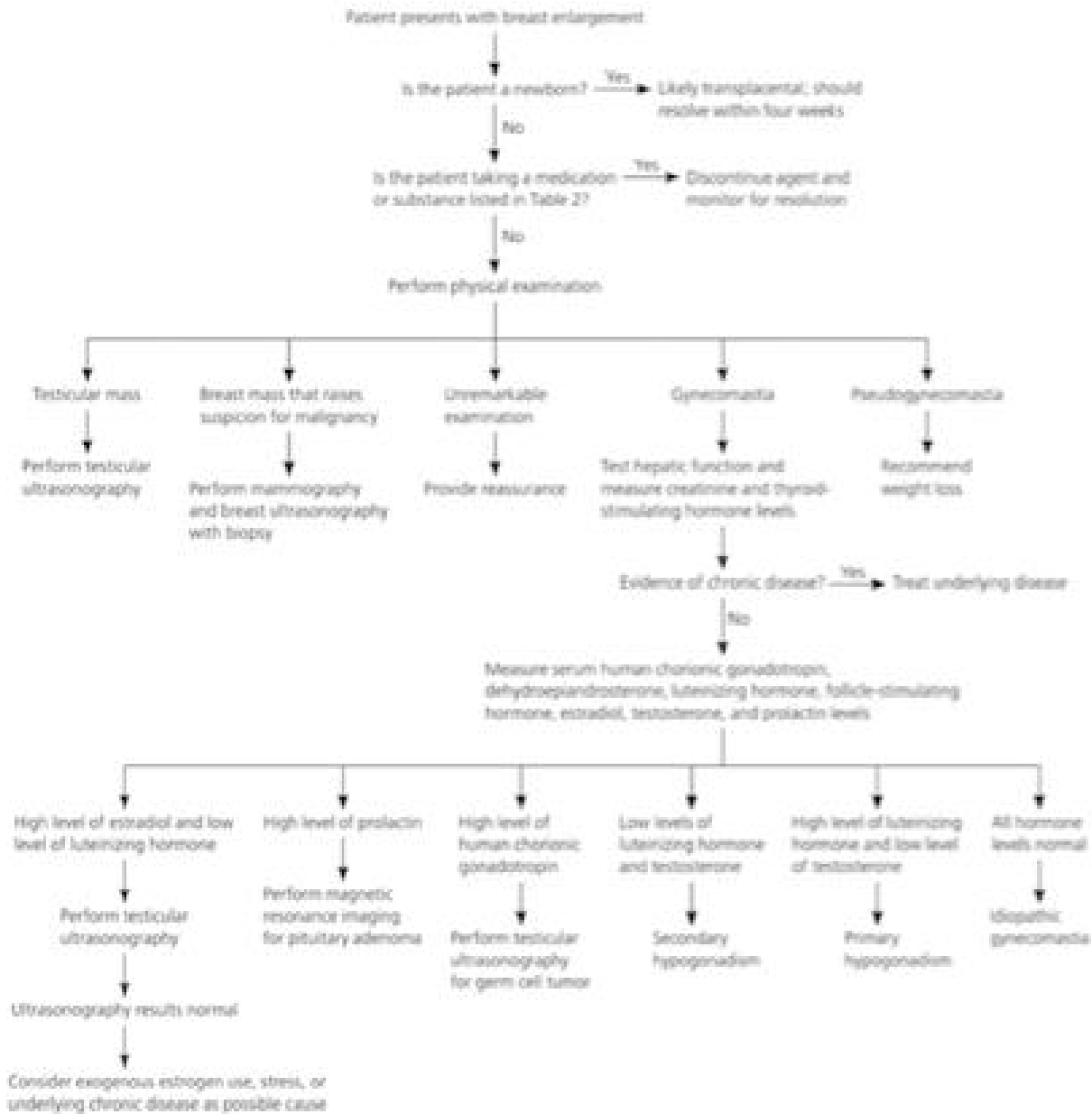

Figure 3. Algorithm for the diagnosis of gynecomastia

History

- Duration of symptoms
- Localized symptoms, such as a palpable mass, breast tenderness or enlargement, and nipple discharge
- History of an undescended testis, mumps, or liver or kidney disease
- Detailed history of medications, supplements, illicit drugs, anabolic steroids
- History of coping with potential distress caused by breast condition

Physical examination

- Height, weight
- Signs of feminization, current Tanner stage
- Stigmata of liver disease
- Breast and overlying skin
- Regional lymph nodes
- Thyroid
- Scrotum

Figure 4. Pointin history and physical examination related to diagnosis of gynecomastia

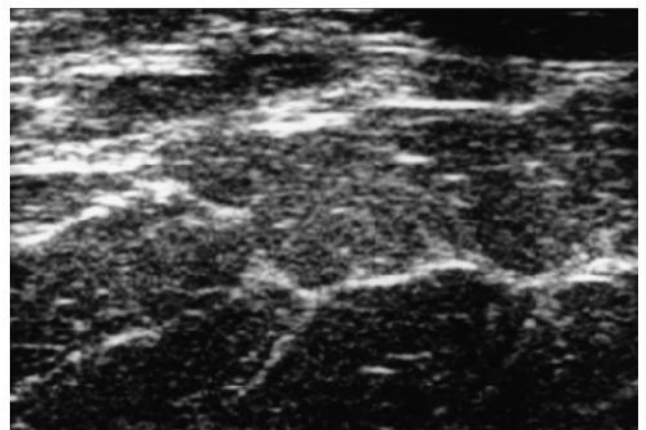


Figure 5. An ultrasound (US) of an obese pseudogynecomastia 12 year-old boy showing accumulation of adipose tissue in the breast

Mammography (MMG) is the primary imaging when there is any suspicion of malignancy. Breast ultrasonography (USG),

(Figure6) scrotal USG and abdominal computerized tomography (CT) of the abdomen can also be used as well as magnetic resonance imaging of the pituitary. A percutaneous biopsy (Figure7) should be taken, at times, when it is difficult to differentiate gynecomastia and breast cancer. (Jurayyan 2016; Cuhaci *et al.*, 2014; Dickson 2012, Piourde *et al.*, 1983; Muroz *et al.*, 2010).

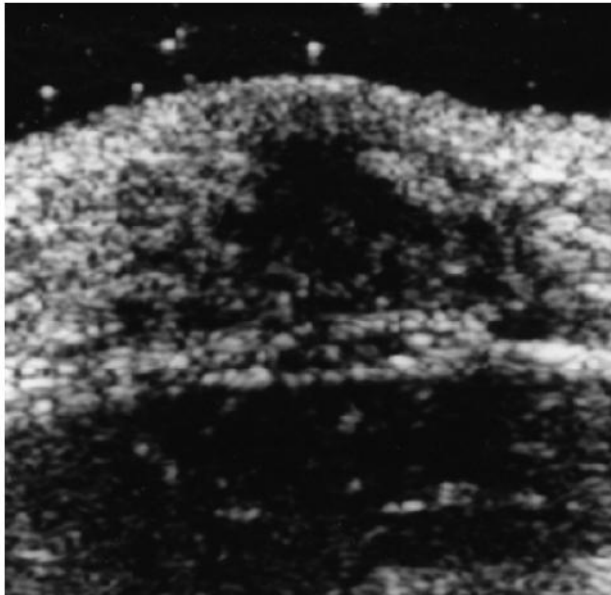


Figure 6. An ultrasound (US) of a 13 year-old boy with gynecomastia, showing breast development

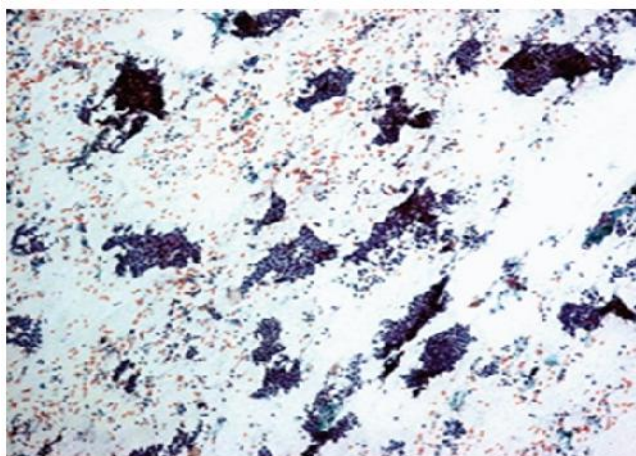


Figure 7. Photomicrograph of hypercellular smear in a patient with ductal cells in fibroadenoma

**Management of Gynecomastia**

Most cases of gynecomastia regress overtime without treatment. However, if gynecomastia is caused by an underlying conditions such hypogonadism, malnutrition or Cirrhosis, these conditions need treatment. If the patient taking medications that can cause gynecomastia, the clinician may recommend stopping or substituting them with other medication. In adolescents with no apparent cause, gynecomastia often goes away without treatment in less than 2 years. Reassurance and frequent follow up 3-6 months that’s what needed. However, treatment may be necessary if gynecomastia does not improve on its own or if it causes significant (Ruth *et al.*, 2011).

**Medical Treatment (pharmaceutical)**

Although no medical treatment causes complete regression of gynecomastia, they may provide partial regression, or symptomatic relief. Several agents regulate the hormonal imbalance. The major medical intervention options are androgens, anti-estrogens and aromatase inhibitors. The androgen testosterone replacement can be used to improve gynecomastia secondary to hypogonadism.

**Table 1. Gynecomastia associated disorders**

Type	Details
Idiopathic	No known cause
Exposure to exogenous estrogens	• Dermal and hair preparations (e.g. lavender and tea tree oils)
	• Milk and meat of cows treated with estrogens
Illness	• Liver disease (e.g. cirrhosis)
	• Renal failure
	• Thyrotoxicosis
	• Malnutrition
Neoplasia	• Adrenal
	• Testicular
Congenital adrenal hyperplasia	• (Late-onset) 21-hydroxylase deficiency (21-OHD)
	• 11-beta-hydroxylase deficiency
	• Overexpression of aromatase

**Table 2. Drug induced gynecomastia**

DRUG	MECHANISM
Amiodarone	Unknown
Calcium channel blockers (diltiazem, verapamil, nifedipine)	Unknown
Central nervous system agents (amphetamines, diazepam, methylodopa, phenytoin, reserpine, tricyclic antidepressants)	Unknown
Cimetidine	Androgen receptor antagonism
Cytotoxic agents (alkylating agents, vincristine, nitrosoureas, methotrexate)	Primary hypogonadism due to Leydig cell damage
Flutamide	Androgen receptor antagonism
<b>Hormones</b>	
• Androgens	Aromatization to estrogens; other mechanisms?
• Estrogens	Direct stimulation of the breast
• Human chorionic gonadotropin	Stimulation of testicular Leydig cell estrogen secretion
Isoniazid	Isoniazid
Ketoconazole, metronidazole	Inhibition of testosterone synthesis
Marijuana	Androgen receptor antagonism
D-penicillamine	Unknown
Phenothiazines	Elevated serum prolactin
Spirolactone	Androgen receptor antagonism; at high doses, interference with testosterone biosynthesis
Theophylline	Unknown

Topical preparations are preferable as they lead to more steady state levels of testosterone in the body as compared with the injectable forms, which can worsen breast enlargement by aromatizing to estradiol. In recent years, anti-estrogens such as tamoxifen and anastrozole have been shown to be effective. More studies are needed to assess the effectiveness of aromatase inhibitors such as anastrozole and testolactone, which are powerful agents that block estrogen. However, further randomized controlled trials are still needed to assess the effectiveness and safety of such drugs in children (Khan *et al.*, 2004; Maura *et al.*, 2009).

### Surgical treatment

Surgical treatment should be individualized to each patient. Numerous techniques have been described for the correction of gynecomastia and the surgery is forced with a wide range of excisional and liposuction procedures. The most frequently encountered complication was a residual subareolar lump. Although skin excess remains a challenge, it can be satisfactorily managed without excessive scarring. A practical approach to the surgical management of gynecomastia, should take into account breast size, consistency, skin excess and skin quality. However generally it is not recommended until the testis has reached adult size, because if surgery is performed before achieving puberty, breast tissue may regrow (Fruhstorfer and Malata 2003; Brown *et al.* 2015; Kasieis Ka and Antoszewski 2013). If pseudogynecomastia is suspected no work up is needed and the patient can be reassured that weight loss will lead to resolution of pseudogynecomastia. If necessary liposuction procedures can reduce breast enlargement secondary to subareolar fat accumulation.

### In Summary

Gynecomastia is not considered rare in childhood and adolescent. The spectrum is variable, although, the majority is idiopathic. There is various recognized causes including chronic disorders such as liver and renal or thyroid disorders. Also various drugs have been associated with the developmental of gynecomastia.

### Acknowledgement

The authors would like to thank Miss Hadeel N. Al Jurayyan for her help in preparing this manuscript.

### REFERENCES

- Basaria, S. 2010. Androgen abuse in athletes: detection and consequences. *J. Clin. Endocrinol. Metab.*, 95(4): 1533-1543
- Biro, F.M., Lucky, A.W., Huster, G.A., Morrison, J.A. 1990. Hormonal studies and physical examination in adolescents gynecomastia. *J Pediatr.*, 116(3): 450-455
- Brown, R.H., Chang, D.K., Siy, R., Friedman, J. 2015. Trends in surgical correction of gynecomastia. *Semin Plast Surg*, 29(2): 122-30
- Carlson, H.E. 2011. Approach to the patients with gynecomastia. *J Clin Endocrinol Metab*, 96(1):15-21
- Cuhaci, N., Polat, S.B., Evranos, B., Ersoy, R., Cakir, B., 2014. Gynecomastia: Clinical evaluation and management. *Indian J Endocrinol Metab.*, 18(2): 150-8
- Deepinder, F., Braunstein, G.D. 2012. Drug-Induced Gynecomastia: an evidence based review. *Expert Opin Drug Saf.*, 11(5): 779-95
- Derkacz, M., Chmiel-Perzynskal, Nowakoski, A. 2011. Gynecomastia- a difficult diagnostic problem. *Endokrynol Pol.* 62(2): 190-202
- Dickson, G. 2012. Gynecomastia *Am Fam Physician.* 1, 85(7): 716-722
- Fentiman, I.S., Fourquet, A., Hortobagyi, G.N. 2006. Male breast cancer. *Lancet* 367(9510):595-604
- Fruhstorfer, B.H., Malata, C.M. 2003. A systematic approach to the surgical treatment of gynecomastia. *Br. J. Plast. Surg.*, 56(3):237-46
- Gikas, P., Mokbel, K. 2007. Management of gynecomastia: an update. *Int J Clin Pract*, 61(7):1209-15
- Glenn, D., Braunstein, M.D. 2007. Gynecomastia *N. Engl. J. Med.*, 357:1229-123
- Handelsman, D.J., Dong, Q. 1993. Hypothalamo-pituitary gonadal axis in chronic renal failure. *Endocrinol Metab Clin North Am.*, 22(1): 145-61
- Hassan, H.C., Cullen, I.M., Casey, R.G., Rogers, E. 2008. Gynaecomastia: an endocrine manifestation of testicular cancer. *Andrologia*, 40(3): 152-7
- Jurayyan, N.A. 2016. Childhood Gynecomastia, A mini Review *IJC EndocrinolMetab.*, 2(1)12-15
- Karagiannis, A., Harsoulis, F. 2005. Gonadal dysfunction in systemic diseases. *Eur. J. Endocrinol*, 152(4): 501-513
- Kasielska, A., Antoszewski, B. 2013. Surgical management of gynecomastia: an outcome analysis. *Ann Plast Surg.*, 71(5):471-5
- Khan, H.N., Rampaul, R., Blamey, R.W. 2004. Management of physiological gynaecomastia with tamoxifen. *Breast*, 13(1): 61-5.
- Ladizinski, B., Lee, K.C., Nutan, F.N.U., William Higgins, H. Federman, D.G. 2014. Gynecomastia; Etiologies, Clinical Presentation, Diagnosis and Management; *South Med J.*, 107(1): 44-49
- Lanfranco, F., Kamischke, A., Zitzmann, M., Nieschlag, E., Klinefelter's Syndrome. *Lancet.* 2004; 364(9430):273-83.
- Mauras, N., Bishop, K., Merinbaum, P., Emeribe, U., Agbo, F., Lowe, E. 2009. Pharmacokinetics and Pharmacodynamics of anastrozole in prepubertal boys with recent-onset gynecomastia. *J Clin Endocrinol Metab.*, 94(8):2975-2978
- Munoz, C.R., Alvarez, B.M., Munoz, G.E., Raya, P.J.L., Martinez, P.M. 2010. Mammography and ultrasound in evaluation of male breast disease. *Eur Radiol.*, 20(12): 2797-2805
- Narula, H.S., Carlson, H.E. 2014. Gynecomastia-pathophysiology, diagnosis and treatment. *Nat Rev Endocrinol*, 10(110): 684-98
- Nuttall, F.Q. 2010. Gynecomastia *Mayo Clin Proc.*, 85 (10):961-962
- Plourde, P.V., Kulin, H.E., Santner, S.J. 1983. Clomiphene in the treatment of adolescent gynecomastia, Clinical and endocrine studies. *AM J Dis Child.*, 137(11):1080-2
- Ruth, E.J., Cindy, A.K., M Hassan, M, 2011. Gynecomastia evaluation and current treatment options. *Ther Clin Risk Manag*, 7:145-148
- Wollina, U., Goldman, A. 2011. Minimally invasive esthetic procedures of the male breast. *J Cosmetic dermatol.*, 10(2): 150-5