



## Full Length Research Article

### ANTI-TUMOR ACTIVITY OF NEWCASTLE DISEASE VIRUS STRAINS (AF 2240 AND V4-UPM) ON AOM-INDUCED ACF IN SPRAGUE–DAWLEY RATS

<sup>1,\*</sup>Rowa M. Assayaghi, <sup>2</sup>Aied M. Alabsi, <sup>1</sup>Abdul Manaf Ali and <sup>3</sup>Gumballi Swethadri

<sup>1</sup>Department of Biotechnology, Faculty of Bioresources and Food Industry,  
University Sultan Zainal Abdin, Terengganu, Malaysia

<sup>2</sup>Faculty of dentistry, University of Malaya, Kuala Lumpur, Malaysia

<sup>3</sup>Department of Pathology, Faculty of Medicine, University Sultan Zainal Abdin, Terengganu, Malaysia

#### ARTICLE INFO

##### Article History:

Received 22<sup>nd</sup> November, 2016  
Received in revised form  
20<sup>th</sup> December, 2016  
Accepted 27<sup>th</sup> January, 2017  
Published online 28<sup>th</sup> February, 2017

##### Key Words:

NDV, AF2240, V4-UPM,  
ACF, AOM, FU.

Copyright©2017, Rowa M. Assayaghi et al. This is an open access article distributed under the Creative Commons Attribution License, which permits unrestricted use, distribution, and reproduction in any medium, provided the original work is properly cited.

#### ABSTRACT

Azoxymethane rat model is a well-established, well-appreciated, and widely used model of experimental colon carcinogenesis. Anti-tumor activity of Newcastle disease virus (NDV) strains AF2240 and V4-UPM was evaluated *in-vivo* to investigate the effect of different doses of NDV on the development of aberrant crypt foci (ACF) in Sprague–Dawley rats initiated with the colon carcinogen azoxymethane (AOM). The total number and crypt multiplicity as well as the degree of dysplasia of ACF were significantly decreased in treated groups with high doses of NDV compared to the groups which treated with low NDV doses. We also investigated the efficacy of the combination of NDV and 5-FU on the development of ACF in rats' colon. RT-PCR of some colon cancer markers (COX-1 and COX-2) and histopathological studies were carried out and had confirmed ACF results which showed significant decreased of ACF numbers.

#### INTRODUCTION

Colon carcinogenesis is a multistep process in which pre-neoplastic lesions accumulate in mucosa cells, finally leading to neoplastic transformation. Many molecular events have been suggested to play a role in the transition from normal colon mucosa to cancer, such as the activation of oncogenes, the inactivation or loss of tumour-suppressor genes and mutations in DNA repair genes (Vogelstein and Kinzler, 1996; Edelmann and Taketo, 2009). The present therapeutic regimens, chemotherapy and radiotherapy have not much improved the survival of the patients with metastases. In addition to limited efficacy, these therapeutic regimens may also have side effects. The goal of cancer therapy is to promote the death of cancer cells without causing much damage to normal cells. A number of viruses with an ability to kill cancer cells while sparing normal cells have been discovered. Such viruses are referred to as oncolytic viruses (Nelson, 1999). Oncolytic viruses can increase sensitivity of tumor cells to chemotherapy and radiotherapy. Many studies confirmed the synergistic effect of the combination of chemotherapy with virotherapy that may enhance the potency chemotherapy effect

with lowest doses without decreasing the antitumor activity (Al-Shammari and Yaseen, 2012). Newcastle disease virus (NDV) is classified as a virus with inherent oncolytic properties which its anti-cancer effect was first reported by Cassel and Garret in 1965. Since then NDV has been investigated for its anti-cancer effects and scientists are interested in NDV because it can replicate up to 10000 times better in human neoplastically transformed cells than in most normal human cells (Nelson, 1999; Liu and Kim, 2005; Omar *et al.*, 2003). Aberrant Crypt Foci (ACF) is readily distinguishable morphological changes within the colonic mucosa of rodents that may contribute to the stepwise progression to colon cancer (Bird, 1995). The formation and growth of ACF are associated with induction of colon tumors in rats and are influenced by exposure to chemo-preventive agents. Useful animal models of colon carcinogenesis are needed not only to study the mechanisms of pathogenesis but also to establish therapeutic and preventive measures (McLellan *et al.*, 1991; Edelmann and Taketo, 2009). In this study, we investigated the anti-tumor activity of NDV strains AF2240 and V4-UPM on colon cancer in Sprague–Dawley rats. The effects of the NDV strains AF2240 and V4-UPM on colon cancer was confirmed by study the number and size of ACF by methylene blue method. RT-PCR of some colon cancer markers (COX-1 and COX-2) and histopathological studies were also performed and had confirmed ACF results.

\*Corresponding author: Rowa M. Assayaghi,

Department of Biotechnology, Faculty of Bioresources and Food Industry, University Sultan Zainal Abdin, Terengganu, Malaysia.

In addition, we also investigated the efficacy of the combination of NDV and 5-Fluorouracil (5-FU) on the development of ACF in rats' colon.

## MATERIALS AND METHODS

### Propagation and Purification of NDV Strains AF 2240 and V4-UPM

NDV was propagated in allantoic fluid of 9–11 days-old embryonated chicken eggs at 37 °C for 2–4 days. The allantoic fluid was harvested and the pure virus collected and stored at -80°C. NDV purified as previously described (Chambers and Samson, 1980; Yusoff *et al.*, 1996). The virus titer was determined by a hem agglutination test with freshly prepared young chicken red blood cells (Alexander, 1988).

### Animals

A total of 45 adult male 5–6 week-old Sprague–Dawley rats in the weight range of 150–180 g were procured from the Animal Research and Service Centre (ARASC), Universiti Sains Malaysia (USM), Kelantan, Malaysia. The animals were housed in polypropylene cages under hygienic conditions in the departmental animal house. All rats were clinically healthy and were fed with *ad libitum* and clean water. Before initiating the experiments, rats were adapted to the laboratory conditions for a week.

### Animal Experimental Protocol

The experimental protocol was approved by Animal Ethics Committee; with an ethic no. (UniSZA/AEC 02/09/03). At 6 weeks of age, 45 rats were randomly assigned to 9 groups with 5 rats in each group so that there were no differences in body weight among the rat groups.

The nine groups of rats were as follows;

- A negative control (NC) served as normal control and were administrated with normal saline only,
- A positive control (PC) group were administrated only AOM,
- (AFLD), group which received low doses of NDV AF 2240,
- (V4LD), group which were given low doses of NDV V4-UPM,
- (AFHD), group that received high doses of NDV AF 2240,
- (V4HD), group which received high doses of NDV V4-UPM,
- (AFFU), group which received both NDV AF 2240 and 5-Fluorouracil,
- (V4FU), group which received both NDV V4-UPM and 5-Fluorouracil,
- (FU), group that received only 5-Fluorouracil.

Both azoxymethane (AOM) (Sigma, USA) and 5-Fluorouracil (5-FU) (Hospira, Australia) were given to rats according to body weight, AOM dose was 15 mg/kg and 5-FU dose was 12 mg/kg. All rats (except the negative (NC) group) were then administered a subcutaneous injection of 15 mg/kg AOM with a second dose of 15 mg/kg AOM administered one week later. Four weeks post AOM treatment; rats were administrated

intraperitoneal injections of 8 doses of NDV and 5-FU. NDV and 5-FU doses were administrated once daily for four successive days; then if no toxicity was observed doses were given on the 6<sup>th</sup>, 8<sup>th</sup>, 10<sup>th</sup>, and 12<sup>th</sup> day (No therapy was given on days 5<sup>th</sup>, 7<sup>th</sup>, 9<sup>th</sup>, or 11<sup>th</sup> day). A week later, those rats were fasted for 12 hours overnight, after euthanasia by intramuscular injection of 0.01µL Xylazil (100mg/mL) and 0.1µL Ketamil (100mg/mL) (Troy Laboratories, Australia); rats were sacrificed and then colons and other organs were removed, and 20mg of fresh colon tissues were quickly taken and kept in *RNA Later* solution (Sigma, USA) at -80 °C until used for RNA extraction (Bird, 1987; Qing *et al.*, 2008; Bird and Good, 2000).

### Body weight and mortality

Record of body weight changes and mortality of all rats were kept throughout the study. The rats were weighed at the beginning of the experiment and twice a week, and finally before sacrificing them.

### Quantification of Aberrant Crypt Foci (ACF) in Rat's Colon by Methylene Blue Method

The entire colon was removed and washed thoroughly with ice-cold PBS, PH 7, slit open from cecum to anus, and fixed flat between 2 pieces of filter paper in 10% buffered formalin. Glass microscope slides were placed on top of the filter paper to ensure that tissue remained flat during fixation. After 12–24h, the colon was placed inside a sterile Petri dish then stained with 0.2% methylene blue for 5–10 min, placed mucosal-slide-up on the slide, viewed with a light microscope. Under the light microscope by 40X, a scalpel was used to excise the aberrant crypt foci (ACF) of the interest and the surrounding normal crypts (Bird, 1995; Dani *et al.*, 2007).

### Tissue Sections Preparations and Histopathological Study of Rats' Organs

For histological observation, fresh tissue pieces of colon, liver, kidney and spleen from the 9 groups of rats were taken. All samples were placed in tissue embedding cassettes and fixed 10% buffered solution for minimum 48h. Following fixation, the specimens were dehydrated in ascending grades of alcohol by Automatic Tissue Processor (Leica ASP 300S, Germany) for 18–24h. Tissues were embedded in paraffin wax and blocks were made by using Tissue Embedding Center (Leica EG 1160, Germany). Sections were made 5–7µm thick by Semi-Motorized Rotary Microtome (Leica, Germany) and were double stained with hematoxylin and eosin (HE) stain. All prepared histological sections were viewed in a light microscope equipped with a Olympus digital camera (Olympus, Japan) (Bird and Lafave, 1995; McLellan *et al.*, 1991). Livers, kidneys and spleens histological sections were diagnosed for any signs of abnormalities or colon cancer metastasis.

### RNA Preparation and Reverse Transcription Polymerase Chain Reaction (RT-PCR) of Colon Tumor Markers (COX-1 and COX-2) on rats' colon tissues

Colons from 9 groups of rats were removed, 20 mg of fresh tissues of the colons were quickly taken and kept in *RNA Later* solution (Sigma, USA) at -80°C to be used for RNA isolation. Disruption of tissue samples was done by using mortar and

pestle in liquid nitrogen and grinded the tissue samples to a fine powder. Total RNA was isolated from the tissue samples according to innuPREP RNA extraction kit (analytikjena, Gerneny). Pure total RNA was reversely transcribed into cDNA with Revert Aid™ Premium first strand cDNA synthesis kit (Fermentas, USA). Into a RNase free tube, 2µL of total RNA, 1µL of random hexamer primer, 1µL of 10mM dNTP, 4 µL of 5X RT buffer, 1µL of Revert Aid™ Premium enzyme and 11 µL of nuclease-free water were added. Then the tube was centrifuged and incubated at 25°C, reaction was terminated by heating at 85°C for 5 minutes. After that, first strand of cDNA with human specific primers for COX-1 and COX-2 and β-actin by RT-PCR was done.

Primers sequences were as follows: (a) β-actin, sense: 5'-GTGGACATCCGCAAAGAC-3' and antisense: 5'-TCAACGCAATGTGGGAAG-3'; (b) COX-1, sense: 5'-TGC-ATG-TGG-CTGTGG-ATG-TCA-TCA-A-3' ; and antisense: 5'-CAC-TAA-GAC-AGA-CCCCTC-ATC-TCC-A-3' ; (c) COX-2, sense: 5'-ACT-TGC-TCA-CTTTGT-TGA-GTC-ATT-C-3' and antisense: 5'- TTT-GAT-TAG-TAC-TGT-AGGGGT-TAA-TG-3' (Raju and Bird, 2003). In a PCR tube, 10X green buffer 2.5 µL, 10 mM dNTP 0.6 µL, forward primer 0.35 µL (1.0 mg/mL), reverse primer 0.35 µL (1.0 mg/mL), 10X dream Taq polymerase 0.1 µL, cDNA 2 µL (Fermentas, USA) and distal water 19.1 µL were added. Briefly, 40 cycles of PCR amplification were performed at 94°C for 5 min, 94°C for 30 sec, 55°C (COX-1 and COX-2) and 58°C (β-actin) for 30 sec, 72°C for 30 sec and 72°C for 5 min in a 25 µL reaction mix. PCR products were separated by 1.5 g/L agarose gel electrophoresis and visualized by UV transillumination after ethidium bromide staining; mRNA expression of genes was assessed by correcting housekeeping gene β-actin, which served as an internal control.

### Statistical analysis

The statistical significance was assessed using one-way analysis of variance (ANOVA). All values were expressed as mean ± SE and a value of  $P \leq 0.05$  was considered significant as compared to the respective control groups using IBM SPSS 20 statistical package for Microsoft Windows (SPSS Inc. Chicago, IL, USA).

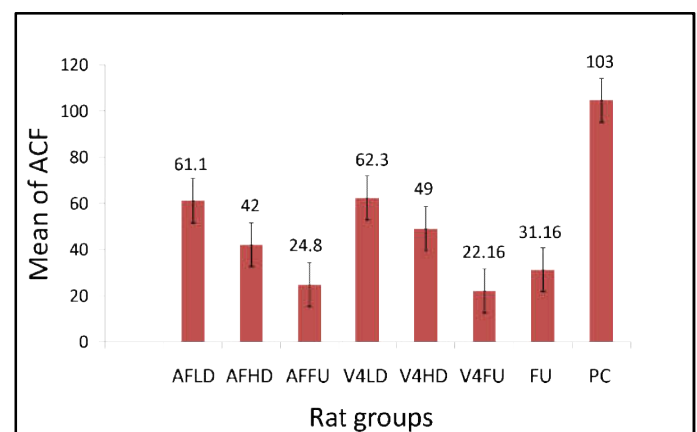
## RESULTS

In this study, slight increases in body weights of all rat groups with time was recorded; however, there was no a statically significant difference in body weight among the rats groups ( $P > 0.05$ ). In addition, there were no clinical signs of toxicity in any of the rat groups; this was evident by the absence of mortality, normal animal behavior, improved body weight gain, normal blood tests and no macroscopically visible alterations in the major organs of all treated and non-treated groups of rat. Methylene blue method was done to determine and count the number of aberrant crypt foci (ACF) in each group of rats, also to determine the number of foci containing ACF in each rat group which is important to detect the effective of NDV strains and combination treatment with 5-FU on the development and number of ACF in different rat groups. Negative control group of rat was free of ACF (ACF=zero), so we did not show the data of this group in the table and some figures only mentioned in figure 3 and figure 5. Data of ACF number (ACF/colon) is summarized in Table 1 (except negative control group).

**Table 1. The Effectiveness of different doses and combination of NDV treatment on AOM-induced ACF formation in the rats' colons. Total number of rats= 40, n=5/group. Negative (normal) control (NC) group was not included in this table. There was significant difference ( $P \leq 0.05$ ) of ACF among the rat groups compared to positive control (non-treated) group**

Rat Groups	Total NO of ACF	Number of foci containing (ACF)					
		1 crypt	2 crypts	3 crypts	4 crypts	5 crypts	>5 crypts
PC	618	150	112	101	100	98	57
AFLD	367	98	76	60	50	45	38
AFHD	252	70	50	44	35	33	20
AFFU	149	35	30	29	25	20	10
V4LD	374	88	79	66	58	50	33
V4HD	294	70	66	57	49	30	22
V4FU	133	35	33	25	20	10	10
FU	187	45	40	35	30	22	15

PC= Positive control (non-treated) group, AFLD= Rats were treated with NDV strain AF2240 low dose, AFHD= Rats were treated with NDV strain AF2240 high dose, AFFU= Rats were treated with NDV strain AF2240 + 5-Fluorouracil, V4LD= Rats were treated with NDV strain V4-UPM low dose, V4HD= Rats were treated with NDV strain V4-UPM high dose, V4FU= Rats were treated with NDV strain V4-UPM + 5-Fluorouracil, FU= Rats were treated with 5-Fluorouracil.

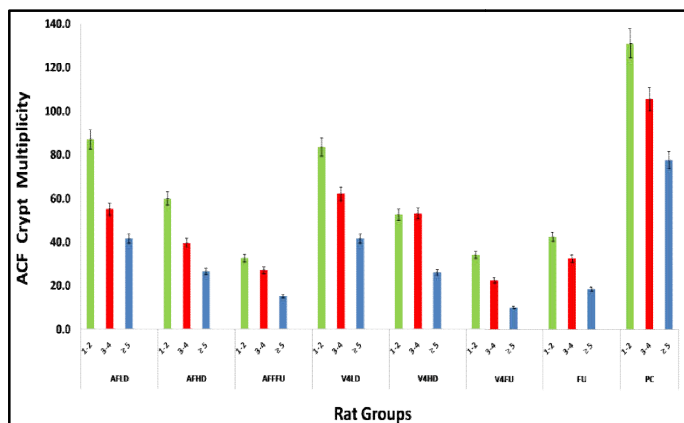


PC: Positive control (non-treated) group, AFLD: Rats were treated with NDV strain AF2240 low dose, AFHD: Rats were treated with NDV strain AF2240 high dose, AFFU: Rats were treated with NDV strain AF2240 + 5-Fluorouracil, V4LD: Rats were treated with NDV strain V4-UPM low dose, V4HD: Rats were treated with NDV strain V4-UPM high dose, V4FU: Rats were treated with NDV strain V4-UPM + 5-Fluorouracil, FU: Rats were treated with 5-Fluorouracil.

**Figure 1. The mean of ACF in each group. All values are expressed as means and ± SE, n= 8 groups. Negative control (NC) group was free of ACF (ACF=zero) and was not included in this figure**

The ACF numbers from methylene blue method were found to be significantly decreased ( $P \leq 0.05$ ) in combination treatment groups (NDV + 5-FU) and also in rats were given NDV high doses compared to other rat groups (Table 1 and Figure 1). Moreover, there was significant difference ( $P \leq 0.05$ ) of ACF among the rat groups compared to positive control (non-treated) group. The highest number of ACF was found in the positive (non-treated) group (Table 1 and Figure 1). Average crypt multiplicity defined as the mean number of crypt/focus/colon which growth feature of ACF. In this study, crypt multiplicity was categorized into primal ACF (1-2 crypts/ focus), intermediate ACF (3-4 crypts/ focus) and

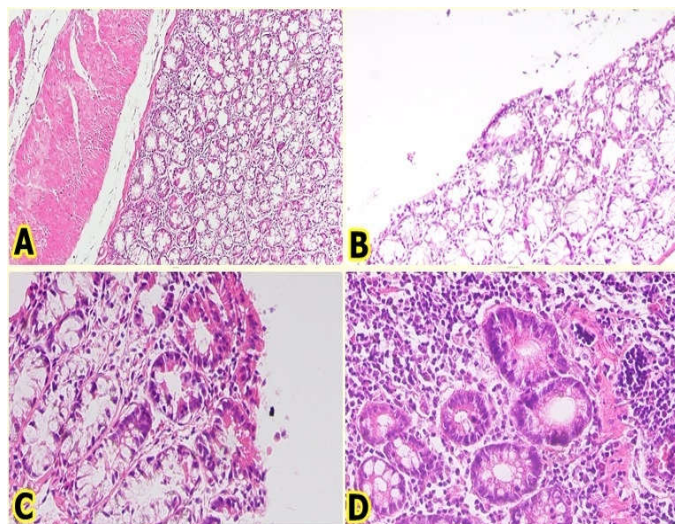
advanced ACF ( $\geq 5$  crypts/ focus) of each group of rats (except negative control group) (Figure 2), this classification has been shown to be predictors of the incidence of colorectal cancer in carcinogen-treated animals (see discussion). A direct correlation between the number of crypt multiplicity of ACF (crypts/ focus) and impact of treatment so that the higher number means less influence for treatment and vice versa. The number of intermediate and advanced ACF (ACF 3-4 and ACF  $\geq 5$ ) was significantly decreased ( $P \leq 0.05$ ) in rats were given the combination treatment (NDV + 5-FU) and also in rat group that was given NDV high doses compared to other rat groups (Figure 2). As shown in the figure 2, the intermediate and advanced crypt multiplicity was found in a high number in the positive (non-treated) group compared to other rat groups.



PC: Positive control (non-treated) group, AFLD: Rats were treated with NDV strain AF2240 low dose, AFHD: Rats were treated with NDV strain AF2240 high dose, AFFU: Rats were treated with NDV strain AF2240 + 5-Fluorouracil, V4LD: Rats were treated with NDV strain V4-UPM low dose, V4HD: Rats were treated with NDV strain V4-UPM high dose, V4FU: Rats were treated with NDV strain V4-UPM + 5-Fluorouracil, FU: Rats were treated with 5-Fluorouracil.

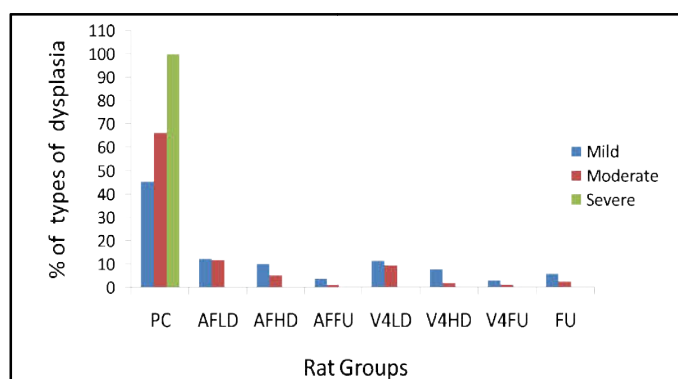
**Figure 2. Mean of ACF crypt multiplicity. Crypt multiplicity was categorized into primary ACF (1-2 crypts/ focus), intermediate ACF (3-4 crypts/ focus) and advanced ACF ( $\geq 5$  crypts/ focus). Negative control (NC) group was free of ACF (ACF=zero) and was not included in this figure**

Blind examinations of the rat colon HE-stained sections were performed by a pathologist. Histopathological classification of colon tissue sections was based on the following criteria; mild dysplasia was characterized as having elongated, crowded and pseudo-stratified nuclei with well-preserved polarity and normal or slightly reduced number of goblet cells. And moderate dysplasia was characterized as having elongated, more crowded and pseudo-stratified nuclei with well-preserved polarity and more reduced number of goblet cells than in mild dysplasia. Moreover, severe dysplasia was characterized as having enlarged, round or ovoid nuclei with prominent nucleoli. The polarity of the nuclear in severe dysplasia is partially lost and the number of the goblet cells is significantly reduced or completely lost (Qing *et al.*, 2008) (Figure 3). Determination the type of dysplasia by HE-stained sections was done to study the effect of different doses of NDV and combination treatment with 5-FU on the different types on dysplasia of each rat group. From rat colon HE-stained sections there were different types of ACF dysplasia were seen in different rat groups, while the severe dysplasia was only seen in the PC group of rats. However; in negative control (NC) group; there were no signs of dysplasia or toxicity observed and showed normal colonic his to architecture (Figure 3).



**Figure 3. Rat colon H&E-stained sections. (A) Normal colonic histo-architecture (X10) (B) Mild dysplasia was characterized as having elongated, crowded and pseudostratified nuclei with well-preserved polarity and normal or slightly reduced number of goblet cells (X20), (C) Moderate dysplasia was characterized as having elongated, more crowded and pseudostratified nuclei with well-preserved polarity and more reduced number of goblet cells than in mild dysplasia (X 40), (D) Severe dysplasia was characterized as having enlarged, round or ovoid nuclei with prominent nucleoli. The polarity of the nuclear in severe dysplasia is partially lost and the number of the goblet cells is significantly reduced or completely lost (X40)**

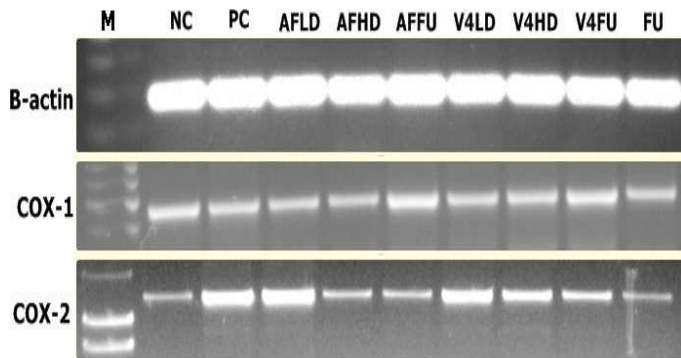
In addition, tissue sections of livers, kidneys and spleens of 45 rats (including the negative control) were observed by a pathologist and reported normal and no signs of colon cancer metastasis. In the present study, number of each type of dysplasia was also performed to determine the effect different doses of NDV and combination treatment with 5-FU on degree and number of dysplasia of every studied group (except negative control group). Severe ACF dysplasia was only found and observed in the positive control (non-treated) group, while mild and moderate ACF dysplasia exhibited in other rat groups (Figure 4).



PC: Positive control (non-treated) group, AFLD: Rats were treated with NDV strain AF2240 low dose, AFHD: Rats were treated with NDV strain AF2240 high dose, AFFU: Rats were treated with NDV strain AF2240 + 5-Fluorouracil, V4LD: Rats were treated with NDV strain V4-UPM low dose, V4HD: Rats were treated with NDV strain V4-UPM high dose, V4FU: Rats were treated with NDV strain V4-UPM + 5-Fluorouracil, FU: Rats were treated with 5-Fluorouracil.

**Figure 4. Percentage of types of ACF dysplasia. Severe dysplasia only exhibited in positive control (PC) group. Negative control (NC) group was free of ACF (ACF=zero) and was not included in this figure**

Significant decreased in number and type of ACF dysplasia was observed in rats were administrated the combination treatment (NDV+5-FU) and high doses NDV ( $P \leq 0.05$ ) compared to other rat groups (Figure 4). To elucidate the interaction between COX-1 and COX-2 and NDV strains treatment, rats were injected by different doses of NDV strains and 5-FU and expression of COX-1 and COX-2 was detected by RT-PCR. The measurement of gene expression of COX-1 and COX-2 of the different rat groups gave the effect indication of treatment with NDV and also with combination with 5-FU. As mentioned in many previous studies that COX-2 expression is elevated in colorectal adenoma and colorectal cancer (see discussion). In the current study, COX-2 was highly expressed in positive control (PC) and NDV low dose treated groups of rats while showed lower level of expression in the rest groups,  $\beta$ -actin which served as an internal control was expressed in all samples at equal level (Figure 5).



**M:** Marker, **NC:** Negative control group, **PC:** Positive control (non-treated) group, **AFLD:** Rats were treated with NDV strain AF2240 low dose, **AFHD:** Rats were treated with NDV strain AF2240 high dose, **AFFU:** Rats were treated with NDV strain AF2240 + 5-Fluorouracil, **V4LD:** Rats were treated with NDV strain V4-UPM low dose, **V4HD:** Rats were treated with NDV strain V4-UPM high dose, **V4FU:** Rats were treated with NDV strain V4-UPM + 5-Fluorouracil, **FU:** Rats were treated with 5-Fluorouracil.

**Figure 5. RT-PCR observed expression of colon tumor markers (COX-1 & COX-2) in rats' colon tissues of 9 groups of rats,  $\beta$ -actin served as an internal control**

## DISCUSSION

Many reports showed the possibility of NDV as a therapeutic agent in cancer treatment, from studies both in animal models and in human clinical trials which showed favorable results (Omar *et al.*, 2003; Krishnamurthy *et al.*, 2006). Numerous studies have used ACF in animal models as a biological endpoint for testing the efficacy of chemo-preventive agents. Moreover, using ACF as an end-point rather than the number of colon tumors gives the advantage of shorter study duration with generation of quantifiable results. The growth, morphological and molecular features of ACF support the contention that ACF are putative pre-neoplastic lesions in colorectal cancer (Cheng and Lai, 2003; Corpet and Taché, 2002). In this study, results of methylene blue method showed significant decrease of ACF, also reduced number and degree of ACF dysplasia were observed from histological study in NDV treated rats compared to positive non-treated rats ( $P \leq 0.05$ ). Characteristics of ACF, such as size and crypt multiplicity, also have been shown to be predictors of the incidence of colorectal cancer in carcinogen-treated animals. It has been suggested that only ACF with a crypt multiplicity at four or more correlate with later development of tumors (Magnuson *et al.*, 1993; Pretlow *et al.*, 1992; Zhang *et al.*, 1992). In this study, crypt multiplicity was significantly

decreased in rats that treated with high doses of NDV ( $P \leq 0.05$ ). These results suggested that NDV has a positive beneficial effect against chemically induced ACF in rats and also confirmed the anti-tumor effect of NDV which reported by many research on various types of cancer, such as Leukemia, breast, lung adenocarcinoma and malignant glioma which showed good and benefit of NDV treatment on these type of cancers on animal models (Gholamreza *et al.*, 2009; Zulkifli *et al.*, 2009; Alabsi *et al.*, 2011; Meng *et al.*, 2012).

Cyclooxygenase (COX), known as prostaglandin-endoperoxide synthase (PTGS), is an enzyme that is responsible for formation of important biological mediators called prostanoids, including prostaglandins. Two isoforms of COX exist; COX-1 is constitutively expressed in all tissues and serves as a haemostatic function, whereas COX-2 up-regulates in response to cytokines and growth factors (Williams *et al.*, 1999). In the present study, we demonstrate the expression of COX-1 and COX-2 in colon mucosa of rat groups. COX-1 was highly expressed in normal and NDV high doses combination (NDV+5-FU) and 5-FU-only treated groups while COX-2 up-regulation was found in other treated rats. It has been confirmed that inhibition of expression of cyclooxygenase-2 (COX-2) has antitumor activity against gastrointestinal carcinoma (Elder *et al.*, 2000). Most studies have demonstrated that COX-2 expression (mRNA and/or protein) is elevated in colorectal adenoma and colorectal cancer as compared with normal mucosa with no apparent change in COX-1 both in vitro or in animal models (Chapple *et al.*, 2000; Khan *et al.*, 2001; Ai-Wen *et al.*, 2004; Hasegawa *et al.*, 2001; Vec *et al.*, 2010). Combination chemotherapy is a common treatment for cancer patients and in the recent years there is a new type of combination had been introduced to the clinical field that by combine chemotherapy with virotherapy and showed oncolytic viruses can increase sensitivity of tumor cells to chemotherapy and radiotherapy (Al-Shammari and Yaseen, 2012). For example Adenoviruses and Herpes Simplex Virus used in combination with some chemotherapy drugs and showed selective destroying tumor cells with minimal toxicity to normal cell. The chemotherapy agent 5-Fluorouracil (5-FU), which has been used against cancer for about 40 years, acts in several ways, but principally as athymidylate synthase inhibitor. Interrupting the action of this enzyme blocks synthesis of the pyrimidine thymidine, which is a nucleoside required for DNA replication (Martuza, 2000; You *et al.*, 2000; Zhang *et al.*, 2003). This study confirmed that combination of NDV and 5-FU had greater antitumor efficacy than NDV or 5-FU alone. This was clear in decreasing the number, crypt multiplicity and degree of dysplasia of ACF and also the down regulation of colon tumor marker (COX-2) in combination treatment groups of rats. These results were in agreement with a previous study which showed the synergistic effect of combination of NDV strain LaSota with Methotrexate on three types of cancer cell lines (Al-Shammari&Yaseen, 2012). Moreover, NDV combination with vinorelbine and carboplatin was tested on non-small cell lung cancer (NSCLC) and the results showed significantly enhanced efficacy, reduce toxicity, synergistic anticancer chemotherapy (Ying, 2011).

Moreover, an *in-vivo* study of synergistic effect of combination of NDV with 5-FU to treat mice with colon carcinoma mentioned that the incidence of complete tumor regression was much higher in the group received both NDV and 5-FU than either 5-FU alone or NDV alone (Lorence and Robert, 2011). While in another study that used NDV strains

with arabinocytocine (Ara-C) in murine myelomonocytic leukemia *in-vivo* proved that no significant difference in the number of leukemia cells was observed between both NDV strains single and booster doses as well between both NDV strains and Ara-C (Alabsi *et al.*, 2011) the differences between results could be strain and/or cell line-dependent.

The mechanisms of synergistic activity in the combination of 5-FU with NDV is thought to be that maybe NDV enhance the antitumor activity of 5-FU by increasing cellular sensitivity to it then enhance induction of cells apoptosis which is previously proved to be induced by NDV (Fabian *et al.*, 2001; Washburn and Schirmacher, 2002; Al-Shammari and Yaseen, 2012). Another mechanism that can explain the synergistic between NDV and 5-FU is that the virus is taken up by tumor cells, and then expresses an enzyme which allows it to interact with the chemotherapeutic agent and resulted in a toxic metabolite in the tumor environment (Sausville, 2004). One more mechanism can explain the synergistic effect showed in a study by Zajakina *et al.*, (2014) which proved the high efficiency of alphaviral gene transfer in combination with 5-FU in a mouse mammary tumor model. That study mentioned that 5-FU is widely distributed to all tissues, including sites of active cell proliferation. In addition to the tumor, the primary target cells are endothelial cells in blood vessels. Therefore, 5-FU treatment leads to massive cell death in places with high vascularization (including the tumor), which may increase tissue permeability to macromolecules and viruses in particular. The concept of enhanced virus intratumoral distribution after drug treatment is also supported by the results of Tseng *et al* (2010) who demonstrated a significant enhancement in tumor vascular permeability and oncolytic Sindbis vector targeting following chemotherapy. In the present study, we observed no adverse effect on the rats when multiple intraperitoneal injections of NDV were administered. Safety of NDV multiple intraperitoneal injections was supported by Anan *et al* study (2001) which also confirmed that multiple NDV doses can be more effective than a single dose and appeared to be necessary to most effectively tumor regression. In conclusion, this study investigated that NDV treatment decreased the number, crypt multiplicity and degree of dysplasia of ACF in rats' colon. We also investigated that COX-2 expression was up- in positive untreated and low doses of NDV treated rats compared to other rat groups. The results also proved that combination of NDV and 5-FU had greater antitumor efficacy than treatment with NDV or 5-FU alone. All these results confirmed that NDV strains are good anti-tumor agents *in-vivo* and can be used in preclinical studies.

### Acknowledgment

We would like to thank Doctor "Jamal Mohammed Baathar" a specialists in Reproductive Health Independent Consultant, Sana'a, Yemen and Doctor "Myat Moe Thwe Aung" a lecturer in Medical Faculty, Universiti Sultan Zainal Abidin, Terengganu, Malaysia for their cooperation in statistical data analysis.

### REFERENCES

Ai-Wen, W.u., Jin, G.u., Zhen-Fu, L.i., Jia-Fu J.I., and Guang-Wei, X. 2004. COX-2 expression and tumor angiogenesis in colorectal cancer. *World J Gastroenterol*, 10, 2323-2326.

- Alabsi, A.M., Abu Bakar, S.A., Ali, R, Omar, A.R., Bejo, M.H., Ideris, A., and Ali, A.M. 2011. Effects of Newcastle Disease Virus Strains AF2240 and V4-UPM on Cytolysis and Apoptosis of Leukemia Cell Lines. *International Journal of Molecular Sciences*, 12, 8645-8660.
- Alexander, D.J. Ed.. 1988. Newcastle disease. In: Newcastle disease virus: an vianparamyxovirus. Netherlands: Kluwer Academic Publishers.
- Al-Shammari, A.M., and Yaseen, N.Y. 2012. In-vitro Synergistic enhancement of Newcastle Disease Virus to Methotrexate cytotoxicity against tumor cells. *Al-Anbar J. Vet. Sci*, 5, 102-109.
- Anan, P., Ropert, M., *et al.* (2001. Newcastle disease virus therapy of human tumor xenografts: antitumor effect of local or systemic administration. *Cancer Letters*, 172, 27-36.
- Bird, R. P., and Lafave, L. M. 1995. Varying effect of dietary lipids and azoxymethane on early stages of colon carcinogenesis: enumeration of aberrant crypt foci and proliferative indices. *Cancer Detect. Prev*, 19, 308-315.
- Bird, R.P. 1987. Observation and quantification of aberrant crypts in the murine colon treated with a colon carcinogen: preliminary findings. *Cancer Lett.*, 37, 147-151.
- Bird, R.P. 1995. Role of aberrant crypt foci in understanding the pathogenesis of colon cancer. *Cancer Letters*, 93, 55-71.
- Bird, R.P., and Good, C.K. 2000. The significance of aberrant crypt foci in understanding the pathogenesis of colon cancer. *Toxicology Letters*, 112-113, 395-402.
- Chambers, P., and Samson, A. 1980. A new structural protein for Newcastle disease virus. *J Gen Virol*, 50, 155-166.
- Chapple, K. S., Cartwright, E. J., Hawcroft, G., Tisbury, A., Bonifer, C., Scott, N., Windsor, A. C., Guillou, P. J., Markham, A. F., Coletta, P. L., and Hull, M. A. 2000. Localization of cyclooxygenase-2 in human sporadic colorectal adenomas. *Am. J.Pathol.*, 156, 545-553.
- Cheng, L., and Lai, M. 2003. Aberrant crypt foci as microscopic precursors of colorectal cancer. *World J Gastroenterol*, 12, 2642-2649.
- Corpet, D.E., and Taché, S. 2002. Most effective colon cancer chemopreventive agents in rats: a systematic review of aberrant crypt foci and tumor data, ranked by potency. *Nutr Cancer*, 43, 1-21.
- Dani, V., Goel, A., Vaiphei, K., and Dhawan, D.K. 2007. Chemopreventive potential of zinc in experimentally induced colon carcinogenesis. *Toxicology Letters*, 171, 10-18.
- Edelmann, M.M., and Taketo, W. 2009. Mouse Models of Colon Cancer. *Gastroenterology*, 136, 780-798.
- Elder, D.J., Baker, J.A., Alitheen, N.B., Moorghen, M., and Paraskeva, C. 2002. Human colorectal adenomas demonstrate a size-dependent increase in epithelial cyclooxygenase-2 expression. *J. Pathol*, 198, 428-434.
- Fabian, Z., Toroosik, B., Kiss, K., Csatory, L.K., Bodey, B., Tigyi, J., Csatory, C., and Szebereny, J. 2001. Induction of apoptosis by a Newcastle disease virus vaccine (MTH-68/H) in PC 12 Rat Phaeochromocytoma cells. *Anti Cancer Res*, 21, 125-136.
- Gholamreza, M.G., Othman, F., Ideris, A., and Rahmat, A. 2009. Dissemination of Newcastle Disease Virus (NDV-AF2240) in Liver during Intratumoral Injection of Xenotransplant Breast Cancer in BALB/c Mice. *Yakhteh Medical Journal*, 11, 303-310.
- Hasegawa, K., Ichikawa, W., Fujita, T., Ohno, R., Okusa, T., Yoshinaga, K., and Sugihara, K. 2001. Expression of

- cyclooxygenase-2 (COX-2) mRNA in human colorectal adenomas. *Eur. J. Cancer*, 37, 1469–1474.
- Khan, K.N., Masferrer, J.L., Woerner, B.M., Soslow, R., and Koki, A.T. 2001. Enhanced cyclooxygenase-2 expression in sporadic and familial adenomatous polyposis of the human colon. *Scand. J. Gastroenterol*, 36, 865–869.
- Krishnamurthy, S., Takimoto, T., Scroggs, R. A., and Portner, A. 2006. Differentially regulated interferon response determines the outcome of Newcastle disease virus infection in normal and tumor cell lines. *Journal of Virology*, 80, 5145–5155.
- Liu, T.C., and Kirn, D. 2005. Viruses with deletion in antiapoptotic genes as potential oncolytic agents. *Oncogene*, 24, 6069–6079.
- Lorence, R.M. and Roberts, M.S.(2011). Cancers treatment using viruse, Fluoropyrimidines and Camptothecins. United States Patent Application Publication, 20,1-6.
- Magnuson, B.A., Carr, I., and Bird, R.P. 1993. Ability of aberrant crypt foci characteristics to predict colonic tumor incidence in rats fed cholic acid. *Cancer Res*, 53, 4499–4504.
- Martuza, R. L. 2000. Conditionally replicating herpes vectors for cancer therapy. *The J. Clin. Investig*, 105, 841-846.
- McLellan, E.A., Medline, A., and Bird, R.P. 1991. Sequential analyses of the growth and morphologic characteristics of aberrant crypt foci: Putative preneoplastic lesion. *Cancer Res* 51, 5270-5274.
- Meng, S., Zhou, Z., Chen, F., Kong, X., Liu, H., Jiang, K., Liu, W., Hu, M., et al. 2012. Newcastle disease virus induces apoptosis in cisplatin-resistant human lung adenocarcinoma A549 cells in-vitro and in vivo. *Cancer Lett*, 317, 56-64.
- Nelson, N.J. 1999. Sbcientific interest in Newcastle disease virus is reviving. *J Natl Cancer Inst* 91, 1708-1710.
- Omar, A.R., Ideris, A., and Ali, A.M. 2003. An overview on the development of Newcastle disease virus as an anti-cancer therapy. *Malays J Med Sci*, 10, 4-12.
- Pretlow, T.P., O’riordan, M.A., and Somich, G.A. 1992. Aberrant crypts correlate with tumor incidence in F344 rats treated with azoxymethane and phytate. *Carcinogenesis*, 13, 1509–1512.
- Qing, L., Jiang, B., Chen, L., and Shan, T. 2008. Dark Aberrant Crypt Foci with activated Wnt pathway are related to tumorigenesis in the colon of AOM-treated rat. *Journal of Experimental and Clinical Cancer Research*, 27, 1-7.
- Raju, J. and Bird, R.P. 2003. Energy Restriction Reduces the Number of Advanced Aberrant Crypt Foci and Attenuates the Expression of Colonic Transforming Growth Factor and Cyclooxygenase Isoforms in Zucker Obese (fa/fa) Rats. *Cancer Res*, 63, 6595–6601.
- Sausville, E. A. 2004. Genes in the service of therapeutic index: Progress for virus directed enzyme prodrug therapy. *J. Clin. Oncol*, 22, 1535-1537.
- Tseng, J.C., Granot, T., DiGiacomo, V., Levin, B., and Meruelo, D. 2010. Enhanced specific delivery and targeting of oncolytic Sindbis viral vectors by modulating vascular leakiness in tumor. *Cancer Gene Ther*, 17, 244–255.
- Vec, J., Ergang, P., Mandys, V., Kment, M., and Pa’Cha, J. 2010. Expression profiles of proliferative and antiapoptotic genes in sporadic and colitis-related mouse colon cancer models. *Int. J. Exp. Pathol.*, 91, 44-53.
- Vogelstein, B., and Kinzler, K.W. (1996. Lessons from hereditary colorectal cancer. *Cell*, 87, 159-170.
- Washburn, B., and Schirmacher, V. 2002. Human tumor cell infection by Newcastle disease virus leads to up regulation of HLA and cell adhesion molecules and to induction of interferons, hemokines and finally apoptosis. *Int. J. Oncol*, 21, 85-93.
- Williams, C.S., Mann, M., and Dubois, R.N. 1999. The role of cyclooxygenases in inflammation, cancer and development. *Oncogene*, 18, 7908–7916.
- Ying, H. 2011. *Enhancing Effect of Newcastle Disease Virus in Combination with Chemotherapy for Patients with Advanced Non-small Cell Lung Cancer*. Master's thesis, Dalian Medical University, Dalian, China.
- You, L., Yang, C.T., and Jablons, D.M. 2000. ONYX-015 works synergistically with chemotherapy in lung cancer cell lines and primary cultures freshly made from lung cancer patients. *Cancer Res.*, 60, 1009-1013.
- Yusoff, K., Tan, W.S., Lau, C.H., Ng, B.K., and Ibrahim, L. 1996. Sequence of the haemagglutinin neuraminidase gene of the Newcastle disease virus oral vaccine strain V4-UPM. *Avian Pathol*, 25, 837–844.
- Zajakina, A., Vasilevska, J., Zhulenkova, D., Skrastina, D., Spaks, A., Plotniece, A., and Kozlovska, T. 2014. High efficiency of alphaviral gene transfer in combination with 5-fluorouracil in a mouse mammary tumor model. *BMC Cancer*, 14, 460-476.
- Zhang, X.M., Stamp, D., Minkin, S., Medline, A., Corpet, D.E., Bruce, W.R. and Archer, M.C. 1992. Promotion of aberrant crypt foci and cancer in rat colon by thermolyzed protein. *J. Natl. Cancer Inst*, 84, 1026-1030.
- Zhang, Z. L., Zou, W. G., Lvo, C. X., Li, B. H., Wng, J. H., Sun, L. Y., Qian, Q. J., and Liu, X. Y. 2003. An armed oncolytic adenovirus system, ZD55-gene, demonstrating potent antitumoral efficacy. *Cell Res*, 13, 481-489.
- Zulkifli, M.M., Ibrahim, R., Ali, A.M., Aini, I., Jaafar, H., Hilda, S.S., Alitheen, N. B., and Abdullah, J. M. 2009. Newcastle disease virus strain V4UPM displayed oncolytic ability against experimental human malignant glioma. *Neurological Research*, 31,3-10.

\*\*\*\*\*