



Full Length Research Article

RELIABILITY OF SINGH INDEX IN GRADING OF OSTEOPOROSIS USING DIGITAL RADIOGRAPHS IN ELDERLY PATIENTS WITH PROXIMAL FEMORAL FRACTURES

***Supradeeptha Challa and Satyaprasad, J.**

Department of Orthopaedics, G.S.L. Medical College, Rajahmundry, Andhra Pradesh, India

ARTICLE INFO

Article History:

Received 30th August, 2013
Received in revised form
16th September, 2013
Accepted 29th October, 2013
Published online 20th November, 2013

Key words:

Osteoporosis,
Digital radiograph,
Singh index.

ABSTRACT

Even though dual energy X-ray absorptiometry is the gold standard for measuring the osteoporosis, many institutes in India doesn't have the facility. Singh index for osteoporosis in plain radiographs have low reliability. So in this retrospective study, we used digital radiographs to analyze the relationship between the Singh index with age, gender, fracture site, laterality, along with intra and inter-observer reliability in elderly patients having proximal femoral fractures due to simple fall.

Materials and Method: Records and digital radiographs of 87 consecutive patients (41 women, 46 men), who were older than 50 years of age and with proximal femoral fracture were retrospectively analyzed.

Results: The grade of osteoporosis was not related to age, gender and laterality in the osteoporotic patients with proximal femur fractures ($p > 0.05$). Over all mean intra-observer, agreement was 0.49 ± 0.1 and inter-observer agreement was 0.21 ± 0.2 (kappa value). Fracture neck femur was mostly seen in grade 2 and 3 of Singh index and intertrochanteric fractures were seen in grade 4 and 5 Singh index.

Conclusion: Even in digital radiographs, there is poor to fair inter-observer reliability, but good intra-observer reliability. Reliability is good in severe osteoporosis than mild to moderate osteoporosis. Older patients with borderline or mild osteoporosis are more prone to intertrochanteric fractures in the hip region.

The risk of femoral neck fractures increases in patients with advanced osteoporosis.

Copyright © 2013 Supradeeptha Challa and Satyaprasad, J. This is an open access article distributed under the Creative Commons Attribution License, which permits unrestricted use, distribution, and reproduction in any medium, provided the original work is properly cited.

INTRODUCTION

90% of proximal femoral fractures occur in patients, older than 50 years (Zuckerman, 1996). The incidence of proximal femur fractures in the elderly persons depends on bone mass, the risk of falling, and the effective neuromuscular protective responses that protect the bones against trauma². Measurement of bone mass is the single best predictor of fracture risk. Skeletal mass can be measured by semi-quantitative techniques for assessing the trabecular morphology of the proximal femur (the Singh index), radiogrammetry, radiographic absorptiometry, quantitative computed tomography, ultrasonography, energy absorptiometry (dual/single energy X-ray absorptiometry) and single or dual photon absorptiometry (Singh *et al.*, 1970; Rosholm, 2001; Yates *et al.*, 1995; Adams, 2009; Benitez *et al.*, 2000;

Ann Laskey, 1996; Adams, 1997; Bilbrey *et al.*, 1988; Wahner, 1987). Singh index is a simple means for measuring bone mass on radiographs. Most of the studies used plain film radiographs for grading osteoporosis using Singh index, with low reliability and cut-off level of osteoporosis (Poggrund *et al.*, 1981; Koot *et al.*, 1996; Masud *et al.*, 1995). Very few studies have been done on reliability of Singh index in digital radiographs. So we have done this study using digital radiographs of pelvis including both hips.

MATERIALS AND METHODS

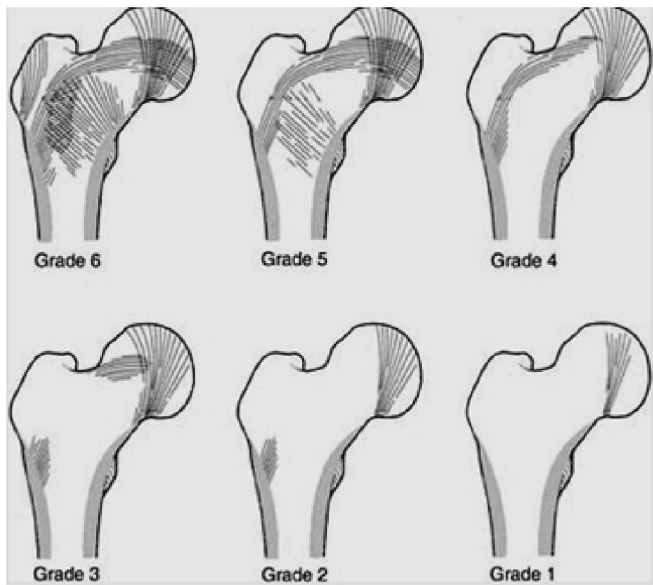
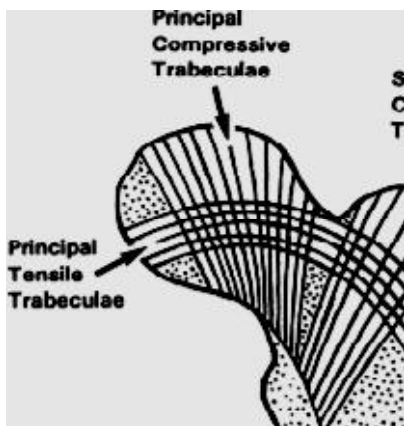
This retrospective study carried on 87 consecutive patients with aged more than 50 years and who sustained fracture neck of femur and intertrochanteric fractures. 46 were men and 41 were women with mean age of 65.82 years (mean \pm S.D \rightarrow 65.82 ± 7.8 years, and range is 51-84 years). Right proximal femur involved in 44 patients and left proximal femur in 43 patients (Table 1). All patients underwent antero-posterior digital radiograph of pelvis with both hip joints with

*Corresponding author: Supradeeptha Challa
Department of Orthopaedics, G.S.L. Medical College, Rajahmundry,
Andhra Pradesh, India

Table 1. patient characteristics

Total number of patients	87
Men (percent)	46 (52.9%)
Women (percent)	41 (47.1%)
mean ±S.D of age of patients	65.82 ± 7.8 years
Number of patients with right side proximal femur involvement (percentage)	44 (50.6%)
Number of patients with left side proximal femur involvement (percentage)	43 (49.4%)
Number of patients with fracture neck femur	45
Number patients with inter-trochanteric fracture	42
Mean ±S.D of age of patients with fracture neck of femur	62.25 ± 5.1 years
Mean ±S.D of age of patients with inter-trochanteric fractures	68.34 ± 8.2 years

hip joints in neutral flexion, abduction, and 15 degrees internal rotation. Two orthopaedic surgeons assessed radiographs of normal side hip, twice with one month apart, using Singh index for grading osteoporosis (Fig 1, 2). The inter- and intra-observer reliability of the evaluations by orthopaedic surgeons was tested (kappa value).



Grade 1: Even the principal compressive trabeculae are markedly reduced in number.
Grade 2: Only the principal compressive trabeculae are prominent, the others have been more or less completely resorbed.
Grade 3: There is a break in the continuity of the principal tensile trabeculae.
Grade 4: Principal tensile trabeculae are markedly reduced in number but still be traceable from the lateral cortex to the upper part of the femoral neck.
Grade 5: The structure of principal tensile and principal compressive trabeculae is accentuated. Ward's triangle appears prominent.
Grade 6: All trabecular groups are normal, and the upper end of the femur completely occupied by cancellous bone.

Figure 1. Singh index for grading of osteoporosis

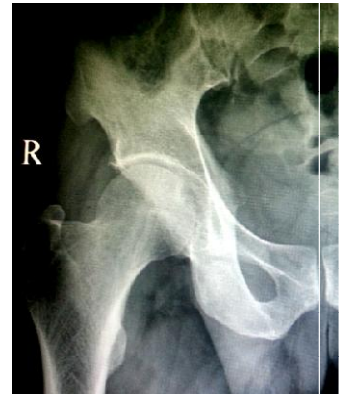

Figure 2. Digital X-ray showing left side fracture neck femur and Singh index grade 3 on right side

RESULTS

Most of the patients with proximal femoral fracture were with grade 3 Singh osteoporosis index. Most of fracture neck femurs patients have Singh grade 2 and grade 1 osteoporosis. Most of patients with inter-trochanteric fractures have Singh grade 3 and more osteoporosis (Table 2). Over all mean intra-observer agreement was 0.49±0.1 and inter-observer agreement was 0.21±0.2 (kappa value) (Table 3).

Table 2. Singh grading index in proximal femur fractures

SINGH INDEX GRADING	Number of patients (%)	FRACTURE NECK FEMUR PATIENTS (percentage)	INTER-TROCHANTERIC FRACTURE FEMUR PATIENTS (percentage)
1	5 (5.7%)	5 (5.7%)	0
2	32 (36.78%)	28 (32.1%)	4 (4.5%)
3	41 (47.1%)	12 (13.7%)	29 (33.3%)
4	4 (4.5%)	0	4 (4.5%)
5	5 (5.7%)	0	5 (5.7%)
6	0	0	0

Table 3. intra-observer and inter-observer values

	KAPPA VALUE
Overall mean intra-observer agreement	0.49±0.1
Overall mean inter-observer agreement	0.21±0.2
Intra-observer agreement in severe osteoporosis	0.62
Inter-observer agreement in severe osteoporosis	0.4
Intra-observer agreement in mild/moderate osteoporosis	0.21
Inter-observer agreement in mild/moderate osteoporosis	0.2

The intra-observer and inter-observer agreement is high in severe osteoporosis (grade 1 and grade 2) (kappa value 0.62, 0.4 respectively) than mild and moderate osteoporosis (grade 4, 5 and grade 3) (kappa value 0.21, 0.2 respectively). Using

multiple regression analysis, the grade of osteoporosis was not related to age, gender and laterality in the osteoporotic patients with proximal femur fractures ($p > 0.05$).

DISCUSSION

Using digital X-rays, over all intra-observer agreement has moderate agreement whereas inter-observer variation has fair agreement. At higher degrees of osteoporosis, intra-observer agreement has substantial agreement whereas inter-observer agreement has fair agreement (Anthony *et al.*, 2005). Among the radiological imaging techniques, plain radiographs are considered to be the least effective for the exact quantification of bone mass (Flynn *et al.*, 2001). On the other hand, it was reported that, Singh grading system had an acceptable level of correlation with bone mineral density measurements of the hip by the DEXA scans, quantitative computed tomography, or microscopic morphometry and could be used to determine the degree of osteoporosis as it might reflect the local cancellous bone quality of the proximal femur (Karlsson *et al.*, 1996; Patel and Murphy, 2006; Wachter *et al.*, 2001). In a study performed in patients older than 60 years of age with trochanteric fractures, stable fractures were found to be more frequent in patients with better bone quality (Lizaur-Utrilla *et al.*, 1987). In another study, a higher Singh index was found in older patients with intracapsular proximal femur fractures compared to the extracapsular ones as a result of shear forces (Scarlat, 2002). In an experimental study, it was stated that, femora with lower mechanical strength were more prone to failure at the femoral neck (Ott *et al.*, 1999). However, these findings and the classical belief are different from the findings of the present study (Ott *et al.*, 1999).

The rate of femoral neck (intracapsular) fractures increased in patients with moderate or severe osteoporosis and the rate of femur intertrochanteric (extracapsular) fractures was higher in patients with borderline or mild osteoporosis. The intertrochanteric fracture is due to degree of osteoporosis along with mechanical factors, especially the type and severity of fall and fracture neck femur is due to significantly reduced bone density in femoral neck region than mechanical factors (longitudinal forces) (Fujii, 1987). It has been stated that it is better to predict the factors relating to falls and fracture than directly osteoporosis. Women with hip fractures are known to be more osteoporotic than men with hip fractures. Besides, the rate of hip fracture increases when the patient's age increases. In our study, the degree of osteoporosis was similar in osteoporotic women and men with proximal femur fractures. No significant change of patient's age with borderline/mild and moderate/severe osteoporosis. Singh index for osteoporosis in digital radiographs has good reliability in assessing lower grades of osteoporosis. In conclusion, digital radiography can be still used as grading of osteoporosis as fractures are more common in severe osteoporosis (Singh index 1-3) where facilities for DEXA scan is available.

REFERENCES

- Adams, J. E. "Quantitative computed tomography." *European journal of radiology*. 2009; 71(3): 415-24.
- Adams, J.E. Single and dual energy X-ray absorptiometry. *European Radiology*. 1997; 7(2): S20-S31.
- Ann Laskey, M. Dual-energy X-ray absorptiometry and body composition. *Nutrition*. 1996; 12 (1): 45-51.
- Anthony J. Viera, Joanne M. Garrett. Understanding Interobserver Agreement: The Kappa Statistic. *Fam med*. 2005; 37(5): 360-63.
- Benitez CL, Schneider DL, Barrett-Connor E, Sartoris DJ. Hand ultrasound for osteoporosis screening in post menopausal women. *Osteoporos Int*. 2000; 11(3):203-10.
- Bilbrey GL, Weix J, Kaplan GD. Value of single photon absorptiometry in osteoporosis screening. *Clin Nucl Med*. 1988 Jan; 13(1): 7-12.
- Flynn W, Lane JM, Cornell CN. Metabolic bone disease. In: Chapman MW editor, *Chapman's Orthopaedic Surgery*. 3rd ed, Philadelphia: Lippincott Williams & Wilkins; 2001. p. 3483-503.
- Fujii M. Experimental study on the mechanism of femoral neck fractures. *Nihon Seikeigeka Gakkai Zasshi*. 1987; 61(5): 531-41.
- Karlsson KM, Sernbo I, Obrant KJ, Redlund-Johnell I, Johnell O. Femoral neck geometry and radiographic signs of osteoporosis as predictors of hip fracture. *Bone*. 1996; 18: 327-30.
- Koot VC, Kesselaer SM, Clevers GJ, de Hooge P, Weits T, van der Werken C. Evaluation of the Singh index for measuring osteoporosis. *JBJS Br*. 1996; 78: 831-834.
- Lizaur-Utrilla A, Puchades Orts A, Sanchez del Campo F, Anta Barrio J, Gutierrez Carbonell P. Epidemiology of trochanteric fractures of the femur in Alicante, Spain, 1974-1982. *Clin Orthop Relat Res* 1987; 218: 24-31.
- Masud T, Jawed S, Doyle DV, Spector TD. A population study of the screening potential of assessment of trabecular pattern of the femoral neck (Singh index): the Chingford Study. *Br J Radiol*. 1995; 68: 389-93.
- Melton LJ, Riggs BL. Risk factors for injury after a fall. *Clinics in Geriatric Medicine*. 1985; 1: 525-39.
- Ott SM. Osteoporosis and osteomalacia. In: Hazzard WR, Blass JP, Ettinger WE, Halter JB, Ouslander JG editors, *Principles of Geriatric Medicine & Gerontology*. 4th ed, New York: McGraw Hill; 1999, pp 1057-84.
- Patel SH, Murphy KP. Fractures of the proximal femur: correlates of radiological evidence of osteoporosis. *Skeletal Radiol* 2006; 35: 202-11.
- Pogrud H, Rigal WM, Makin M, Robin G, Menczel J, Steinberg R. Determination of osteoporosis in patients with fractured femoral neck using the Singh index: a Jerusalem study. *Clin Orthop* 1981; 156: 189-95.
- Rosholm A *et al.* Estimation of bone mineral density by digital X-ray radiogrammetry: theoretical background and clinical testing. *Osteoporos Int*. 2001; 12(11): 961-9.
- Scarlat M. Correlation between osteoporosis and types of fractures of the proximal femur: clinical and X-ray study of 284 cases (French). *Rev Chir Orthop Reparatrice Appar Mot*. 2002; 88: 257-63.
- Singh M., Nagrath A.R., Maini P.S., Changes in trabecular pattern of the upper end of the femur as an index of osteoporosis. *JBJS Am*. 1970; 52(3): 457-467.
- Wachter NJ, Augat P, Hoellen IP, *et al.* Predictive value of Singh index and bone mineral density measured by quantitative computed tomography in determining the local cancellous bone quality of the proximal femur. *Clin Biomech* 2001; 16: 257-62.
- Wahner HW. Single- and dual-photon absorptiometry in osteoporosis and osteomalacia. *Semin Nucl Med*. 1987; 17(4): 305-15.
- Yates AJ, Ross PD, Lydick E, Epstein RS. Radiographic absorptiometry in the diagnosis of osteoporosis. *Am J Med*. 1995; 98(2A): 41S-47S.
- Zuckerman JD. Hip fracture. *N Engl J Med*. 1996; 334: 1519-25.